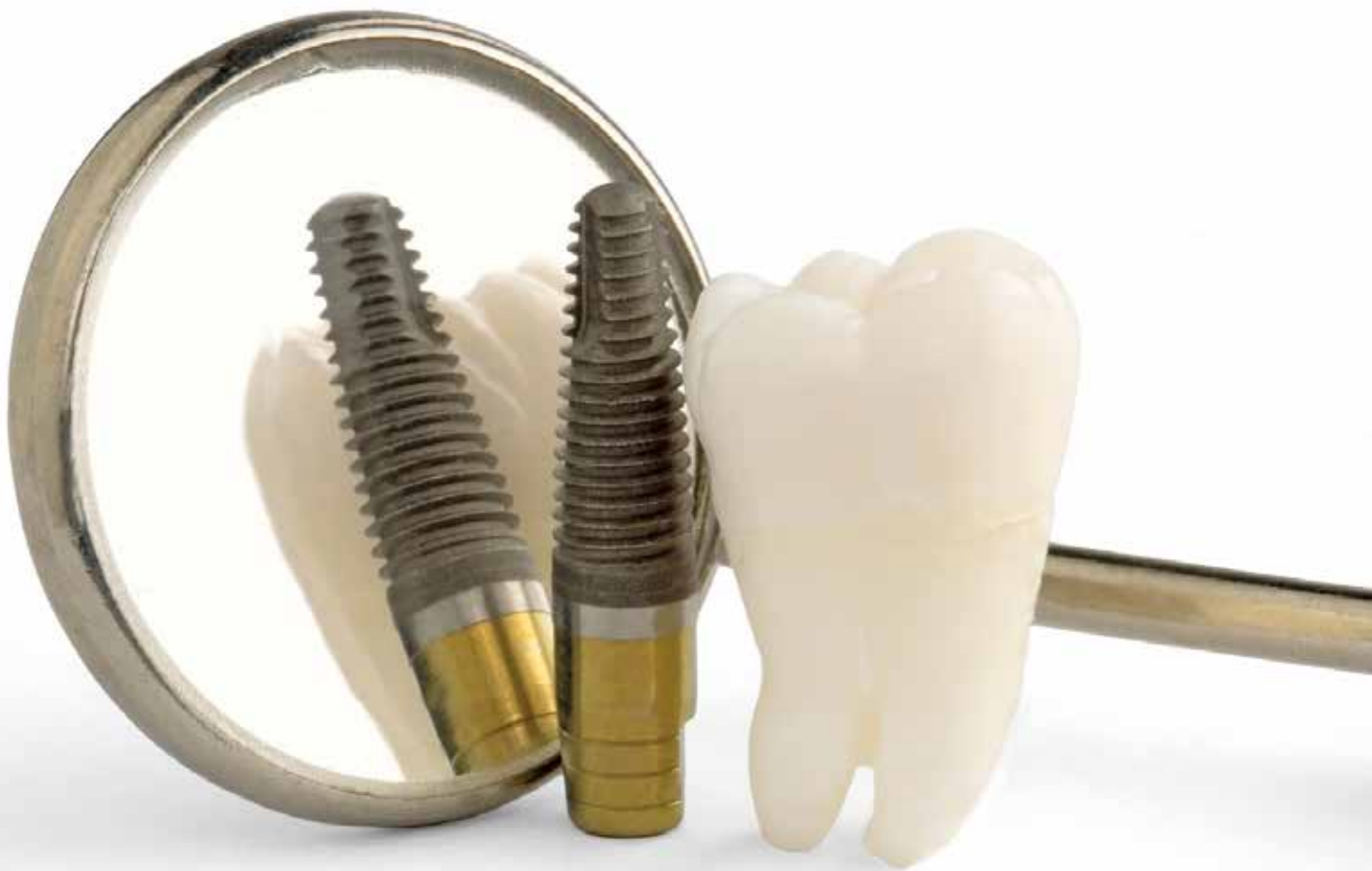

ADI

Association
of Dental
Implantology

A Dentist's Guide to Implantology



INTRODUCTION

During the last decade, implantology has become an indispensable part of mainstream dentistry, helping dentists to improve the quality of life of large patient populations.

Whilst implant treatment could often be a convenient alternative to conventional treatment options, in certain cases, it is the treatment of first choice for the rehabilitation of severe functional, anatomical or aesthetic problems arising from tooth loss. This is probably most striking in the treatment of the severely atrophic mandible.

A couple of decades ago implant treatment was reserved for specialist dental teams working at selected universities or specialist centres who, by and large, treated severely atrophic edentulous patients. In the 90s, indications for implant treatment gradually changed from that of fully edentulous to the partially edentulous cases. With increasing demand, this has resulted in a process of unprecedented research and development in implantology culminating in rapid technological advances and paradigm changes in implant design, materials and components as well as relative ease of the delivery of treatment across all its stages: the patient assessment and treatment planning, implant placement and integration phase, the restorative treatment and the maintenance phases.

Although implant dentistry has evolved to become an important part of clinical practice, unfortunately the coverage of this subject both in the undergraduate and postgraduate curriculum has been rather slow, unstructured and certainly limited. Lack of recognised academic standards and training pathways has generated obstacles for the majority of the busy dentist practitioners who want to offer implant treatment in their practices.

In the UK, the uncertainty concerning the training and provision of implant dentistry finally changed with the publication of the guidelines produced by a working group convened by the GDC/FGDP(UK) in 2005. This document, "**Training Standards in Implant Dentistry**", was revised later in 2008 and then in 2012 and now governs the standards necessary for training and provision of implant dentistry in the UK. Moreover, the GDC has issued a declaration stating "**a UK-qualified general dental practitioner will not be competent to carry out implant dentistry without further training**" (British Dental Journal, 2008).

To conform to the above-mentioned standards for teaching and provision of implant dentistry and to enable general practitioners to gain the necessary competencies for delivering safe and effective implant treatment, the universities, independent individuals or organisations, and institutions such as the Royal Colleges have gradually made available structured postgraduate courses at certificate, diploma and masters levels (e.g. Dip in Imp Dent RCSEd or FGDP(UK), MSc in Implant Dentistry). Today, the UK dentists are fortunate to have highly structured opportunities and pathways (including the ADI's mentoring scheme) for training in implant dentistry compared with many of our European partners.

Currently the framework for postgraduate teaching includes the following basic components:

- Assessed academic learning
- Acquisition of clinical skills and competencies at the workplace under supervision of an experienced local mentor
- Demonstration of clinical activity through an audited logbook and a learning portfolio

The ADI has developed a number of highly focused and structured educational products to help newly qualified dentists to acquire the necessary knowledge and clinical competencies in implant dentistry that are required for independent practice.

The ADI has commissioned an online course – **Ark** – which comprises 13 modules written by some of UK's most distinguished implant experts as a comprehensive and authoritative source of academic learning in implantology. Completion of this online course provides the learner with all the necessary learning objectives in this field. Ark consists of not only a learning resource but also provides quizzes and tasks to test application of knowledge and exercises for self-reflection. This resource may be accessed at www.adiark.org.uk

To complement Ark and to help to fulfil training guidelines, the ADI has established a network of trained clinical mentors who are available to supervise the development of clinical competencies in work-based environments. Finally the ADI has a logbook, which is available as a free membership benefit. This online software enables the clinician to keep an audited record of their implant activity in a completely anonymised and secure way to fulfil the GDC requirements.

Development of clinical competence in implant dentistry requires structured postgraduate training and highly focused CPD activity. Thus, newly qualified colleagues interested in implantology are advised to review their learning requirements carefully and seek advice before embarking on a lengthy study in this professionally rewarding but highly demanding field of dentistry. I would highly commend the ADI as a first port of call for advice in this respect.

The aim of this publication is to provide an overview of the foundations of dental implantology and to discuss how beginners could get involved in this fascinating subject.

Finally, I would like to invite our newly qualified colleagues to join the ADI as new members for whom we have created a special free membership category in their DF1 and DF2 training years.

I trust you will find this guide useful and informative.

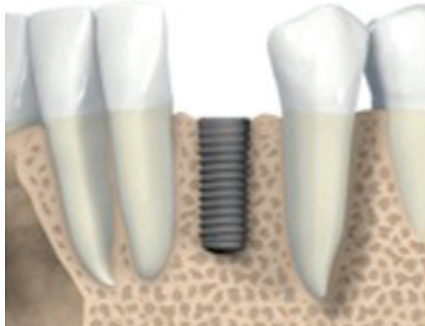Professor Cemal Ucer
ADI President, June 2012

CONTENTS

	WHAT IS DENTAL IMPLANTOLOGY?.....	4
	WHAT TYPES OF IMPLANTS ARE USED TODAY?.....	5
	HOW LONG DO IMPLANTS LAST?	7
	CASE SELECTION AND TREATMENT PLANNING	9
	TOOTH LOSS AND ITS MANAGEMENT.....	13
	THE TIMING OF IMPLANT PLACEMENT.....	15
	DENTAL IMPLANT SURGERY.....	17
	ADVANCED IMPLANT SURGERY, BONE AND SOFT TISSUE AUGMENTATION.....	19
	SURGICAL AFTER-CARE AND COMPLICATIONS.....	20
	IMPLANT RESTORATION	
	A) REMOVABLE IMPLANT OVERDENTURES.....	22
	B) FIXED IMPLANT PROSTHESES.....	27
	MAINTENANCE PHASE OF DENTAL IMPLANTS.....	30
	TREATING PERI-IMPLANT DISEASE.....	33
	THE LATEST DEVELOPMENTS IN DENTAL IMPLANTOLOGY.....	36
	CAREER PATHWAYS AND IMPLANT DENTISTRY.....	38
	MEDICO-LEGAL CHALLENGES IN IMPLANT DENTISTRY	39

WHAT IS DENTAL IMPLANTOLOGY?

Dental implantology is the field of dentistry that is concerned with the replacement of missing teeth and their supporting structures with artificial prostheses anchored to the jawbone.

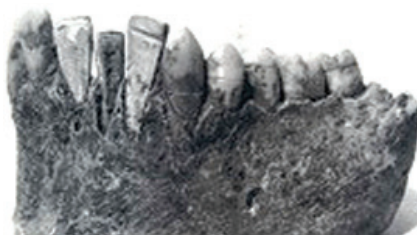

Besides functional problems, tooth loss can lead to psychological problems due to low self-esteem and social impairment thus considerably affecting the quality of one's life.

Indications for implant treatment:

- Restore dental aesthetics
- Restore lost dental function:
 - Chewing
 - Speech
- Space maintenance and occlusal stability
- Orthodontic anchorage
- Convenience and comfort
- Bone preservation and prevention of disuse atrophy after tooth loss

Replacing lost teeth with a bone-anchored device is not a new concept. To successfully replace missing teeth and their supporting structures with artificial teeth has been an aspiration of humankind for centuries.



Mayan dental implants from 600 AD

The Mayan civilization has been shown to have used some of the earliest examples of dental implants. Archaeologists found a fragment of a mandible of Mayan origin, dating from about 600 AD which had three tooth-shaped pieces of shell placed into the sockets of three missing lower incisor teeth.

The phenomenon of osseointegration of titanium implants was discovered by a Swedish orthopaedic surgeon, P I Brånemark, in 1952 who defined osseointegration as “a direct structural and functional connection between ordered living bone and the surface of a load-carrying implant”.

Table: The prerequisite for predictable osseointegration:

- **Hardware:** biocompatibility, implant design features, geometry and surfaces
- **Surgical Technique:**
 - Atraumatic and aseptic surgery
 - Primary implant stability and movement-free healing
- **Host Factors:** bone and soft tissue quality and quantity, infection-free implant bed, systemic and local conditions
- **Restorative factors:** loading conditions; restorative design, abutment selection
- **Maintenance**

It is believed that Professor Brånemark's work in developing the osseointegrated dental implants constituted the birth of the era of the “evidence-based dentistry”. In recent years, there has been a vast amount of scientific research and development in implant design, geometry, materials and techniques with the objective of further improving the success of implant treatment. Most of these developments have focused on how to enhance the process of osseointegration through improvements in implant design and surface modifications. In return, these technological advances have helped to modify many of the established and often complex implant protocols and helped to introduce simplified techniques such as immediate or early loading.

Evidence Based Implant Treatment

Today, there are a multitude of materials, implants, components and techniques available. Understandably, not all of these are equally well documented or successful.

When selecting materials, techniques or recommending a particular modality of treatment in each individual case, the clinician have ethical and medicolegal obligations to base their decision and recommendations on the best available current evidence. In order to do so, an up-to-date knowledge base and critical appraisal of the current evidence is essential.

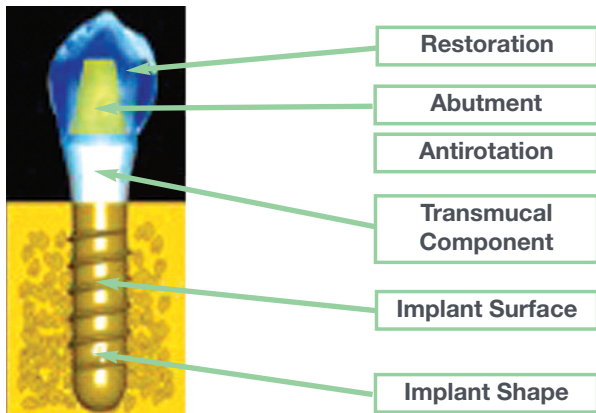
How is the Available Evidence Appraised?

When appraising the evidence there are some questions that need to be asked and guidelines to be followed:

- What is the strength and quality of the available research?
- Are the results of research valid and reliable?
- Are the valid results clinically important?
- Can these valid and important results be applied to my patients?


WHAT TYPES OF IMPLANT ARE USED TODAY?

Modern implants consist of an osseous part that interacts with the bone, a transmucosal component that interacts with the mucosa and then the restoration; this can be a crown or bridge abutment, or anchors for dentures. In recent years, there has been a vast amount of scientific development in implant design, geometry, materials and techniques in order to improve the ease of delivery and success of implant treatment. The majority of designs are cylindrical, or root form in geometry and almost exclusively endosseous, i.e. placed within the alveolar bone rather than subperiosteally or intra-mucosally. Surfaces are normally roughened (microporous) through use of surface preparation (e.g. sand blasting and acid etching) rather than being coated to increase the surface area available for osseointegration.



Dental implant

The materials used commonly for implants include commercially pure titanium, titanium alloys or occasionally ceramic materials (e.g. zirconium dioxide or aluminium oxide).




Microporous surface of a dental implant

Implant Design

Great majority of modern root form dental implants are “**threaded**” in design although the thread pitch or profile can vary significantly between manufacturers. Micro-threaded implants employ small threads around the neck of the implant to engage the dense cortical bone better and to distribute occlusal loads more optimally. This has been shown to reduce the shrinkage of the crestal bone through enhanced biomechanical fixation and loading. Other implants use different thread designs to improve their stability, particularly in softer bone.

Implant surfaces also show variations. Surface hydrophilicity enhances adherence of biomolecules and promotes the initiation of the osseointegration process. Almost all modern implants today have a microporous (rough) surface rather than a relatively smooth machined surface. Roughness increases the surface area available for more “**bone-implant contact**”. Some implant surfaces are treated with bioactive substances such as fluoride to enhance the process of osseointegration. One implant system uses laser etching to promote adherence of hard and soft tissues to the shoulder portion of the implant as it emerges from the crestal bone. It has been suggested that this can help to resist apical migration of the peri-implant tissues.

Macroscopically, an implant may or may not have a polished collar that protrudes above the crestal bone into the soft tissues. Implants that are fully inserted within the alveolar bone are known as “**bone-level implants**”. Restorative components are designed to fit on top of the implant (external connection) or within the implant (internal connection). If an abutment larger in diameter than the diameter of the implant is used – this is known as “**platform switching**” which has been shown to offer distinct mechanical and biological advantages. Clinicians need to be aware of the different implant design features as each implant might require different clinical and radiological monitoring particularly with respect to the position of the bone in relation to the “**shoulder**” of the implant. In case of bone level implants, the crestal bone stability should be measured with reference to the shoulder of the implant where as for implants with polished collars, the bone margin should be measured from the rough/smooth junction of the implant collar.



External implant connection, bone level implant (Straumann), tissue level implant (Straumann)

WHAT TYPES OF IMPLANT ARE USED TODAY?

Different implant designs and procedures are being introduced constantly as implantology continues to evolve. These new products have been subject to varying levels of research and development and clinical documentation with the implications that some materials or procedures may prove to be less reliable or safe in routine use. Since clinicians are bound by ethical and medicolegal responsibilities, the onus is very much on the treating dentist to select the most appropriate procedure or material depending on individual circumstances. In accordance with the current training standards guidance by the GDC, clinicians must ensure that the treatment they offer and undertake must be evidence-based and patient-centred. The dentist must also use a contemporary decision-making process to critically appraise new products and techniques before using them, and must ensure they follow current clinical consensus.

Classification of Implants

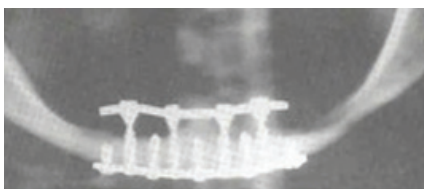
Great majority of modern implants today are endosteal (i.e. placed with alveolar bone) in design.

Endosteal implants are subdivided into several different types characterised by their geometry, shape, surfaces and function and materials:

- Cylindrical or root form implants
- Blade implants and the ramus frame
- Pin implants (Chercheve)
- Disc implants
- Pterygoid or zygomatic implants
- Trans-osteal implants



Blade implant

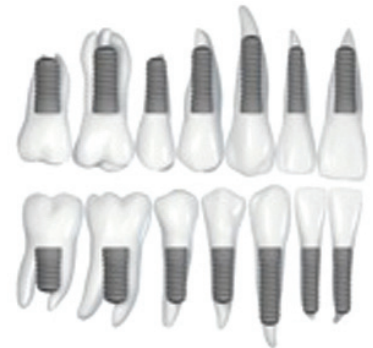

Trans-osteal implants

Cylindrical or Root Form Implants

Cylindrical or root form implants are the most commonly used modern implants in routine dental practice.

Root form implants can show variations with respect to:



Thread Design

If an implant lacks any outer threads this is known as a "Push-fit (non-threaded) implant". Threaded implants, on the other hand, could be solid screws or hollow screws in design. Also screws can be self tapping and non-self tapping. Most modern implant designs are threaded root form screws.

Diameter

Implants are classified according to their general diameter in cross section.


Geometry

Implants can be "tapered" or "parallel sided" in profile. Some surgeons prefer parallel sided fixtures whilst others use exclusively tapered ones. There is no convincing evidence to suggest that one is superior to another design.

One-piece or Two-piece Implants

Implants are manufactured either as one piece (incorporating an integral abutment) or two-piece fixtures (an implant and a separate abutment)

- Regular Platform implants (3.5 - 4.5 mm diameter)
- Wide Diameter implants (usually > 4.5 mm in diameter)
- Reduced Diameter implants (usually < 3.5 mm)
- Mini implants (usually < 3mm in diameter)



One-piece and two-piece implant – courtesy of Straumann AG/ITI

HOW LONG DO IMPLANTS LAST?

Cross-sectional studies have shown implant treatment to be highly reliable and safe in suitably selected patients. Long-term benefits of implant treatment include:

- Cost effective and long lasting solution to tooth loss
- Significant benefits in improving quality of life and well-being of patients
- Prevention of disuse atrophy and deterioration of the jaw bone support

Studies have also shown that implant complications can occur and some implants may fail. Long-term success and prognosis often depends on successful management of a variety of risk factors (e.g. uncontrolled diabetes, history of periodontal disease, bruxism, occlusal trauma etc) that may be present in each individual case. Patients should be fully aware of the effect of these risk factors on the success or survival of their implants and how these modifying factors should be managed to optimise the prognosis.

Success and Survival Rates

Success means that an implant is present at the time of review and fulfils certain pre-established criteria such as no pain, radiolucency, no bone loss, no peri-implant pocketing etc. On the other hand, survival means that, at the time of examination, the implant is simply present in situ but the condition of the implant is not taken into consideration. In other words, survival rates do not take in to account whether or not there are any problems with the implant such as crestal bone loss or deep pocketing. Unfortunately there is little universal agreement on what constitutes success criteria, so different studies are reported using different criteria making direct comparisons of success often impossible.

Survival rates of dental implants have been reported to be in excess of 90% after 15 years. Systematic reviews have also shown no significant difference in survival rates between different implant systems. However, it should be remembered that survival is not the same as success. Long-term problems can occur with dental implants, both biologically (e.g. gingival recession or inflammation) and mechanically (e.g. screw and restoration fractures), which are not represented in survival figures. Studies have shown that in the long-term implant prostheses such as overdentures or large span bridges may be prone to significant mechanical problems. A well planned maintenance and monitoring program is essential to ensure the long-term survival and success of implant treatment.

Risk Factors that Affect the Management of an Implant Case and its Prognosis

Each patient is a unique individual with different anatomical, aesthetic and functional requirements. A detailed risk analysis should be part of the decision-making process during treatment planning. It is said that a clinician may need to assess as much as 60 different risk factors before finalising a treatment plan. (Tonetti, 2000)

The experience and training of the clinician, as well as patient expectations and financial and time constraints should be factored into the risk analysis.

Host (patient) risk factors can be local and systemic:

- Systemic disease (eg uncontrolled diabetes, immunosuppression or certain medication like bisphosphonates)
- Local: radiotherapy, smoking, poor bone quality and density, periodontal disease, occlusal trauma, parafunctional habits and bruxism, endodontic/periapical lesions in adjacent teeth, unfavourable smile line, unrealistic patient expectations and poor soft tissue biotype etc. (Levine & Shanaman, 1995)

What is the Relevance of Biomechanical Implant Function?

When an osseointegrated implant is loaded vertically or horizontally, stress and strain concentrations occur within the bone surrounding the implant at the bone-implant interface. Overloading (excessive concentration of stress), could give rise to loosening or fracture of the implant components such as abutment screws. Overloading could also cause bone loss at the implant-bone interface, giving rise to implant failures.

Successful outcome of implantation therefore depends on reduction and distribution of the occlusal forces transmitted through the implant to the surrounding bone tissue. These forces directly influence the behaviour and response of the host tissue surrounding the implant.

Implants have been designed to minimise excessive stress concentrations and distribute loads evenly.

The fundamental objectives of optimal biomechanical implant design are:

- 1) To minimise stress concentration at the bone-implant interface
- 2) To enhance primary and secondary implant stability within bone
- 3) To reduce and distribute occlusal forces transmitted to the bone-implant interface through optimisation of implant design and surface characteristics

Different implant systems employ different design features in order to improve implant fixation, the percentage of bone-implant contact so as to optimise interfacial stress distribution.

HOW LONG DO IMPLANTS LAST?

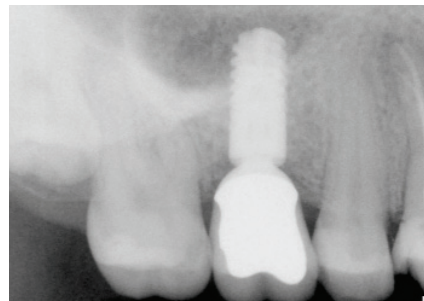
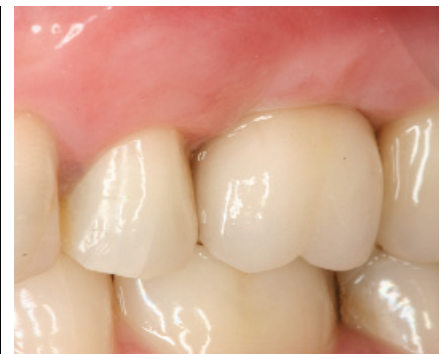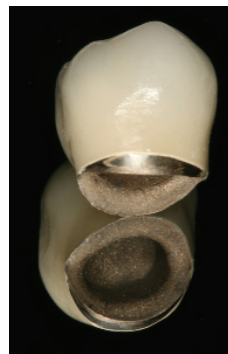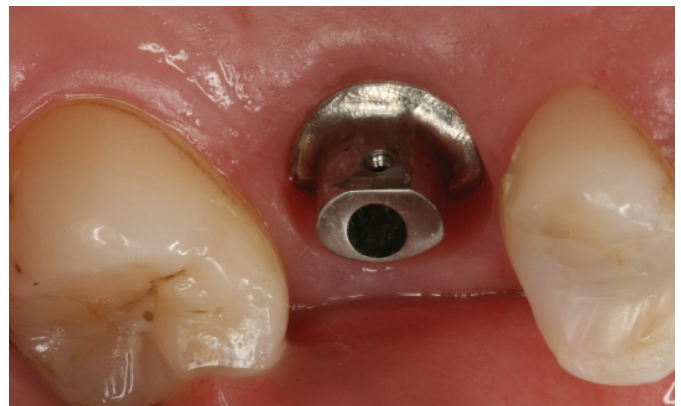
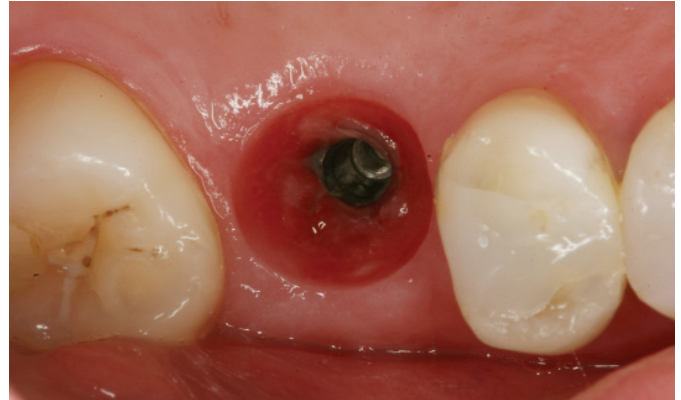Features of leading implant systems:

- Scientifically proven research and development
- Evidence-based clinical use
- Animal experiments
- Valid controlled prospective studies
- Multi-centre clinical trials
- Long-term documentation of their predictability
- Continuous research and development with backward compatibility
- Most leading implant manufacturers provide excellent clinical and technical backup and support
- Well established implant manufacturers also provide product training

During the last two decades, many modifications have been developed to improve the long-term success of implants. Today there are more than 1300 types of dental implants available, in many different materials, shapes, sizes, lengths and with different surface characteristics or coatings.

Whilst there is some evidence to suggest that one implant system may not be superior to others, it should be noted that there are problems in trying to determine the comparative success of different implant systems:

- a) There is a lack of well-conducted randomised clinical trials (RCT) with long-term follow up
- b) There are only a very few comparative studies investigating the survival or success of different implant systems
- c) There is lack of universally used success criteria. Different studies use different criteria which makes comparisons difficult. This affects the homogeneity of trials when carrying out systematic reviews.
- d) Different studies use different outcome measures. Often these are not specified in the publications making it impossible to compare results of different trials.
- e) There is general lack of studies with long-term (five to ten years) follow up.



CASE SELECTION TREATMENT AND PLANNING

As with other areas of dentistry, successful dental implant treatment relies on a rigorous and systematic approach to treatment planning including taking a thorough history of patient's presenting complaint, social history and medical situation. Any pre-existing dental disease should have been treated and brought under control before embarking on dental implant treatment. Care must be taken to properly assess and select the patient for this type of treatment and to ensure not only that the treatment will be successful, but that the patient's expectations will be met or managed.

There are very few absolute medical contraindications for dental implant treatment. The use of bisphosphonates (anti-resorptive medication) has been considered a contraindication for implant treatment due to the possible risk of osteonecrosis of the jaws (known as anti-resorptive agent induced osteonecrosis of the jaw – ARONJ) developing in susceptible patients. However, the current evidence shows that the risk is very small in patients prescribed oral dose of these medications and the risk is dose and time-related (see ADI Guidelines on Bisphosphonates and Anti-Resorptive therapy). Uncontrolled diabetes is also considered to be a relative contraindication.

Contraindications for implant treatment:

- Radiotherapy to the jaw bone
- Untreated intraoral pathology or malignancy
- Untreated periodontal disease
- Uncontrolled drug or alcohol use (abuse)
- Uncontrolled psychiatric disorders
- Recent myocardial infarction (MI) or cerebrovascular accident (CVA) or valvular prosthesis surgery
- Intravenous bisphosphonate (anti-resorptive) therapy
- Immunosuppression - for example following organ transplant or treatment of systemic disease
- Inability to maintain high levels of plaque control (e.g. reduced manual dexterity or mental capacity)

Smoking

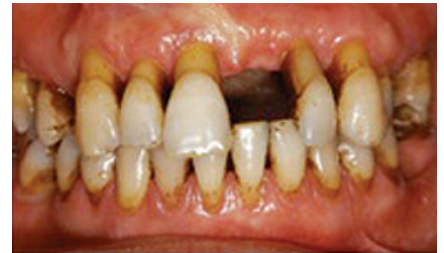This is considered to be a relative contraindication for implant treatment. Whilst implants can initially integrate well even in heavy smokers, there is strong evidence that smoking is associated with increased risk of peri-implant infection and accelerated crestal bone loss as well as poor wound healing.

On the other hand, some studies have shown that good survival rates could be achieved in smokers. Nevertheless, there is convincing evidence that patients who are having more advanced procedures such as bone grafting are more at risk of failure if they smoke. Furthermore there is general agreement that smoking could potentiate the risk of complications occurring in presence of other risk factors such

as poorly controlled diabetes, immunosuppression, untreated periodontal disease etc. Therefore patients should strongly be advised to give up smoking before embarking on dental implant treatment and offered appropriate counselling to do so.

History of Periodontal Disease

Periodontal disease must be controlled and maintained before starting dental implant treatment. Plaque control should be excellent. Many studies report lower implant



survival and success rates in individuals with a history of untreated periodontitis. On the other hand, there is general consensus that implant treatment in patients with a history of treated and well-controlled periodontal disease is not contraindicated, with the majority of studies reporting implant survival in excess of 90% over a period of 3 to 16 years. Nevertheless, although good implant survival rates are reported, there is good evidence to show that significantly higher incidence of long-term peri-implant crestal bone loss occurs in periodontally compromised patients. These individuals would therefore benefit from more intensive professional peri-implant monitoring and maintenance as well as meticulous home care.

Occlusal Conditions and Loading

Peri-implant bone loss happens as a result of plaque-induced inflammatory process occurring at the crestal portion of the alveolar bone surrounding the implant. Like in periodontal disease, a direct cause-effect relationship between dental plaque and peri-implant disease has been conclusively demonstrated (Mombelli et al). Under certain conditions, bone loss can also be initiated as a result of "overloading" at the implant-bone interface. This could potentiate plaque-induced inflammatory changes. In reality, the biological and mechanical factors co-exist and most likely potentiate each other. Thus peri-implant bone loss is commonly seen in presence of both plaque and occlusal overloading in susceptible individuals. Furthermore certain local and systemic conditions could modify the condition of the alveolar bone (e.g. uncontrolled diabetes) making it more susceptible to accelerated shrinkage in response to both biological and mechanical insult.

Patients receiving dental implant treatment therefore require careful long-term management and monitoring of their occlusion especially because dental implants lack the benefit of a periodontal ligament and its proprioceptive function.

Age and Gender

There is no convincing evidence to suggest that age or gender affect the outcome of osseointegration in the short or the long term. This is somewhat a surprising finding, given that, a sudden decline in bone volume and bone mass occurs as a result of ageing and particularly in postmenopausal women.

CASE SELECTION TREATMENT AND PLANNING

Dental implants are effectively ankylosed to the bone, for this reason implants are not placed until the facial skeleton has stopped growing; this being usually about 18 years of age. If this rule is not observed, integrated implants could soon become “submerged” similar to retained deciduous teeth as the permanent dentition continues to erupt.

The Treatment Planning Process

As in other fields of dentistry, adequate case assessment and treatment planning is a prerequisite for satisfactory implant treatment.

Each patient presents with unique set of problems and treatment needs. Only by taking into account all of their individual circumstances including anatomical, functional, and aesthetic requirements can we achieve a realistic, predictable and satisfactory outcome. Lessons can often be learned from failing or failed natural teeth that can improve the new solution.

During the planning stages, many factors are considered for dental implants including patient’s expectations and financial and time constraints. In any given case, there are usually a few treatment options available with the possibility of using different materials or procedures all with different sets of risks, advantages and disadvantages. Care should be taken to thoroughly evaluate the patient before weighing up the treatment options. Only when complete evaluation process is completed a multi-disciplinary treatment plan including all clinicians and the laboratory technician can be made and presented in writing to the patient. Full patient education and information is an integral part of this process.

Table: Diagnosis and treatment planning:

• Patients presenting complaint and wishes and desires
• Dental and social history
• Medical history
• Extra-oral examination including lip and smile lines
• Intra-oral examination including full periodontal charting
• Diagnostic imaging (may be deferred for construction of a radiological stent)
• Additional investigations
• Photography
• Diagnosis and treatment plan presentation
• Written treatment plan and cost estimate
• Patient education and informed consent
• Communication with other members of the team and the referring practitioners

Prosthetically Driven Treatment Concept

One of the cardinal rules in implantology is that the implant placement surgery should be prosthetically driven. This means that the desired final restoration should be first planned and used as a guide for 3-D positioning of the supporting dental implant fixtures. If this cannot be readily achieved, site development (both hard and soft tissue) and regenerative procedures should be considered to allow the correct positioning of the implants according to the restorative requirements of the final case.

Treatment planning should include discussion of, not only the recommended treatment, but all reasonable alternatives such as conventional options, their relative advantages, disadvantages and limitations. The patient should also be fully aware of all possible risks and how best to manage potential complications. Expected outcome of treatment and its long-term prognosis together with modifying risk factors that might affect such prognosis should also be brought to the patient’s attention.

Options of treatment for tooth loss:

- No treatment
- A denture
- A bridge (adhesive or conventional)
- Implant treatment (and its different options)

Once the final restoration is decided, special investigations are undertaken to determine the status of the implant bed and the presence of vital anatomical structures.

Special Investigations

The objective of implant dentistry is to provide patients with durable, functional, aesthetic and easy to maintain prostheses. Three-dimensional restorative planning (with CBCT scanners) is increasingly used to ascertain the difference between an ideal end result and the current situation.

As well as missing teeth, the volume of missing alveolar bone and keratinised tissue and the effects of this loss on the patient’s appearance and function must be evaluated in three-dimensions and within the functional boundaries of the masticatory system.

This will normally involve routine detailed documentation. In addition to the routine medical and dental history that must be taken for every patient, there are a number of additional investigations that may be undertaken:

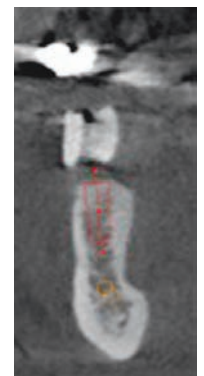
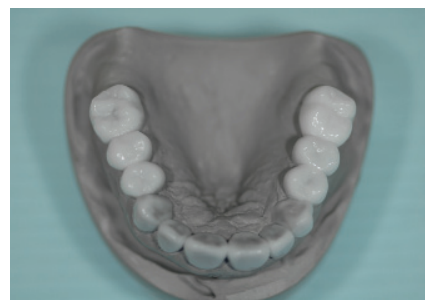CASE SELECTION TREATMENT AND PLANNING

- a) Good-quality clinical photography showing all standard views and site-specific views
- b) Two sets of study casts, one untouched and one used for planning
- c) Facebow and occlusal records for planning of whether the case will be a conformational or reorganised approach (will the existing occlusion be accepted or does the occlusion need to be altered for best results)
- d) A realistic tooth wax up or setup based on the above decision. At this point it will be possible to see whether the definitive restoration is likely to be fixed or removable.
- e) Construction of a radiographic stent based on the tooth setup above with radiopaque markers that will show up on a CT scan
- f) A sectional or full arch scan as appropriate using modern cone beam CT (CBCT)
- g) Analysis with suitable planning software to allow a realistic three-dimensional plan of implant and restorative component positions. This will allow the relationship between the final desired tooth positions and of the existing underlying bone to be visualised in three dimensions.
- h) A decision as to whether sufficient bone exists and whether more advanced surgical procedures will be required to provide bone volume
- i) Where applicable, occasionally the manufacture of a surgical guide manufactured from this plan

Radiographs and CT Scans

Dental panoramic radiographs (DPR) and periapical radiographs (PA) can be used to evaluate sites for dental implant placement. DPRs suffer from magnification distortion and require radiopaque markers for correction of the magnification factor. They should be employed with caution particularly when considering implants in close proximity to vital structures such as the inferior alveolar nerve (IAN). PAs are dimensionally accurate but are limited in their ability to fully incorporate crucial anatomical structures including the inferior dental nerve and the maxillary sinus. Cone beam CT (CBCT) scanning gives an accurate three-dimensional image of the jaws and can be used to measure bone density but radiation dose is higher. To justify the use of CBCT the diagnostic yield should be maximised by using a radiographic stent representing an accurate mock-up of the restored dentition. This facilitates accurate planning of implant placement based on the position of the final restoration. Small field CBCT scans are now available and can provide accurate 3D imaging of smaller areas with much lower radiation exposure.

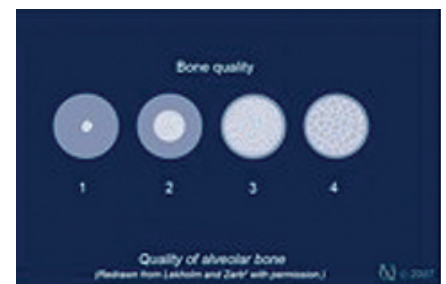
Whilst a CT scan will not be required for every case and occasionally it will be possible to carry out planning without the use of stents, it is highly recommended that this approach is used by all dentists new to implant dentistry until a level of expertise has been achieved where more selective decisions in the treatment planning steps can be taken. Accepted radiological protection principles such as ALARA should be used at all times and risk:benefit analysis should be carried out when making decisions on the choice of imaging for implant placement surgery.



Site Evaluation

Clinical research has demonstrated that bone quality is one of the most significant prognostic factors in implant dentistry. As poor bone support leads to higher failure rates, accurate determination of the available bone quality, density and volume is mandatory to ensure predictable long-term results.

Bone quality is difficult to quantify because of its complex structure. It is a term used to describe the architecture and density of bone as well as its cortical and trabecular bone thickness.



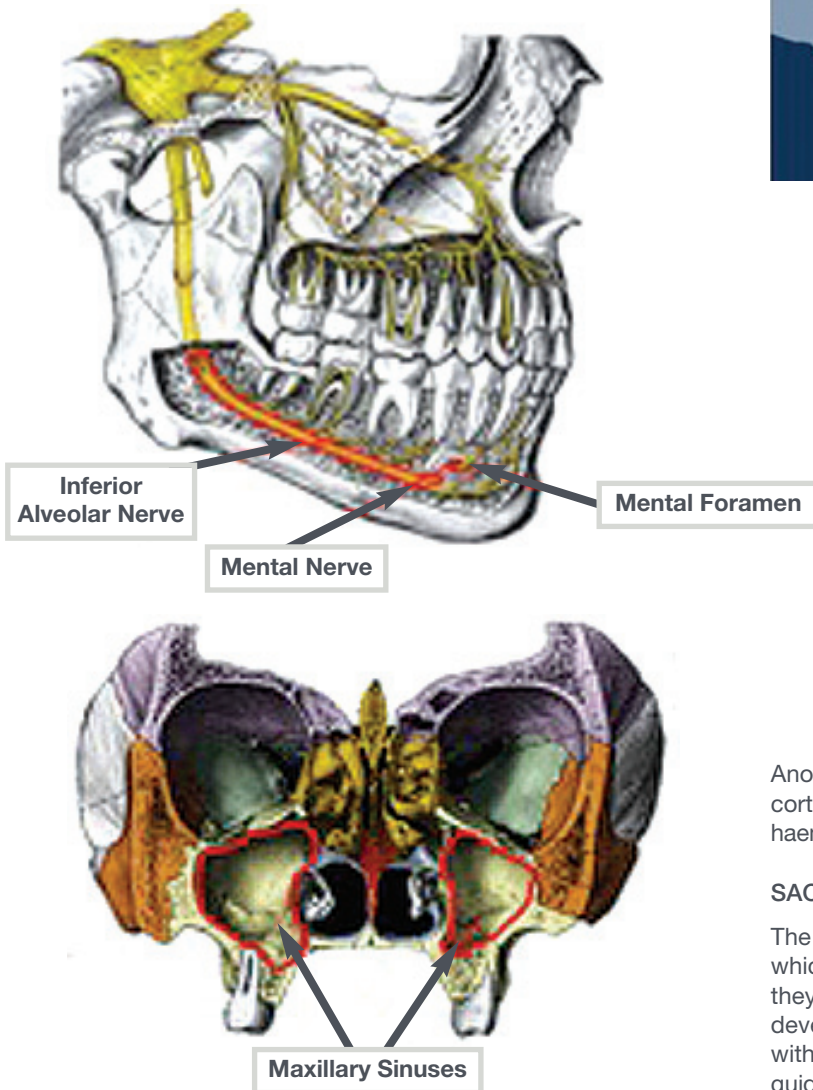
The Lekholm and Zarb (1985) Classification (Types I-IV) based on cortical thickness and trabecular sparseness, although not validated, is used commonly for diagnostic and surgical purposes. Type 1 and Type 2 bones are relatively dense as they mostly consist of thick cortical bone. Type 3 bone is softer and more trabecular whereas Type 4 bone is very soft, consisting of only a very thin layer of outer cortex with very sparse inner core of trabecular bone.

The maxilla has Type 3 bone in the anterior and premolar regions and Type 4 in molar areas. The mandible may have Type 1 bone anteriorly and has Types 2 and 3 bone elsewhere. Studies have demonstrated that higher implant failures occur in softer Type 4 bone. Modified surgical techniques, bone augmentation procedures and implants with certain surface design and characteristics are routinely used to improve the chance of success in case of unfavourable bone quality such as Type 4 bone.

CASE SELECTION TREATMENT AND PLANNING

Bone density and volume can be determined clinically and radiologically. The only validated method of doing so, however, is the CT or CBCT scanning.

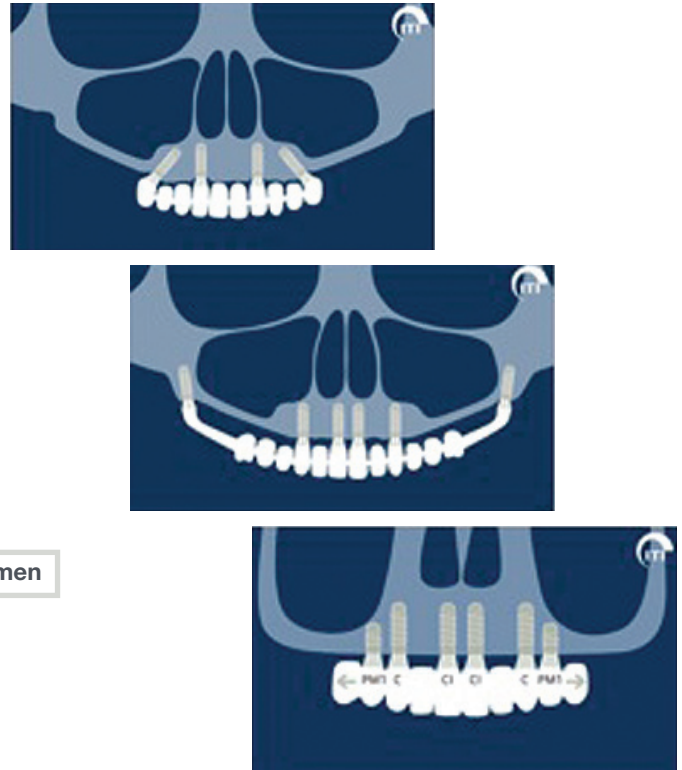
Anatomical Factors



The major anatomical structures that need to be taken into consideration when planning dental implant placement are the maxillary sinus, nasal floor, inferior dental nerve and mental nerves. It should be remembered that the mental nerve sometimes has an anterior loop of up to 4mm.

The ADI has developed and published a set of Guidelines on the prevention and management of inferior alveolar nerve damage. Please see the ADI website for more details.

Short implants, angled implants and in the maxilla, zygomatic and pterygoid implants may be used in special circumstances to avoid encroaching on anatomical structures.



Images provided courtesy of Straumann AG/ITI

Another potential hazard is that perforation of the lingual cortex of the mandible could cause potentially life-threatening haemorrhage due to damage to the sublingual artery.

SAC Classification

The SAC classification is a risk assessment tool (ITI.org), which categorises dental implant cases according to whether they are straightforward, advanced or complex (SAC). It was developed to assist practitioners to select cases that are within their skill level and adopted in the training standards guidelines published by the GDC/FGDP(UK).

Implant treatment is generally considered to be an elective procedure. From medicolegal point of view, the clinician is required to discuss with the patient all associated risk factors and possible complications, including likely prognosis of treatment as well as all possible alternatives so that the patient can make an informed decision on their choice of treatment. For informed consent to be valid, full disclosure of all potential risks and complications is mandatory. This necessitates a detailed assessment and treatment planning process including determination of the SAC classification of the complexity of each treatment.

TOOTH LOSS AND ITS MANAGEMENT

Tooth loss has physiological effects that we need to understand if we are to provide suitable treatment. The most important of these is bone loss and atrophy.

Tooth removal is the single most important factor underlying the loss of alveolar bone which is most pronounced during the first year of after tooth loss. Alveolar bone does not form in absence of teeth and this close association with presence of teeth and bone is maintained throughout life (Misch). A tooth is necessary for the development of alveolar bone and stimulation of bone is necessary to maintain its load bearing capacity: density, quality and volume.

Consequences of Tooth Loss

83% of unopposed teeth are likely to overerupt, and the extent of the overeruption may be marked. The incidence and extent of overeruption is of clinical significance, not only in terms of treatment planning to prevent undesirable vertical movement, but also in the restoration of the edentulous space.

51.6% of unopposed teeth are likely to be involved in premature contacts or excursive interferences (Craddock and Youngson).

Both the functional changes and the anatomical changes that result from tooth loss and the consequent bone atrophy can have a knock-on effect on a patient's wellbeing or quality of life.

The following tables show the effect of tooth loss on bone and hard tissue contour:

Bone	<ul style="list-style-type: none"> • 80% bone loss to basal layer • Disuse bone atrophy in the maxilla and mandible is not limited to the alveolar bone but could extend to the underlying basal bone • Severe resorption of the maxilla can occur causing dental disability • Exposure of the mental nerve (and sometimes inferior dental nerve) occurs, causing compression pain due to dental trauma • The interarch space increases
Soft tissue	<ul style="list-style-type: none"> • Loss of attached keratinised mucosa occurs after tooth loss, superimposed by general reduction in tissue thickness and quality with increasing age • Lip support is lost • Tongue increases in size • Blood supply to the jaw diminishes
Aesthetics	<ul style="list-style-type: none"> • Decreased facial height • Loss of labiomental angle • Deepening of vertical lines in lip and face

Dental Extraction

Often dental implant treatment starts with the extraction of a tooth, and it is something we as dentists undertake readily, most commonly the procedure is to bring about relief of symptoms such as pain or swelling, but may also be necessary as a result of trauma, overcrowding, impaction, or the ravages of periodontal disease, and the list goes on.

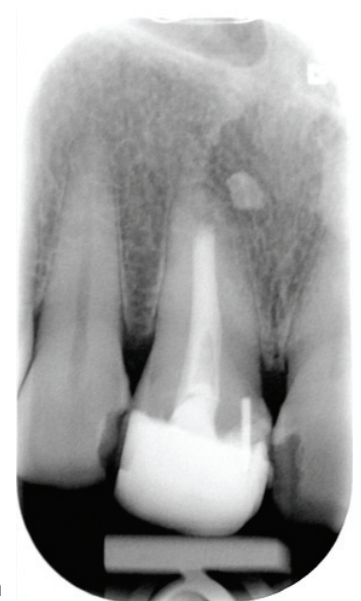In most cases we give little thought to the extraction socket itself, of course we give our patients guidance on post operative care, we tell them not to smoke etc., but do we actually consider the healing process when we apply our forceps, and what will be left behind following the surgery?

We have known for decades that the condition of the implant bed has a huge bearing on implant success and this includes bone volume. The less traumatic the extraction, the better the preservation of bone volume at the site is likely to be. Achieving successful dental implant-supported oral rehabilitation requires long-term biologic integration of fixtures with the surrounding tissue. It follows therefore that when considering implant placement to replace a tooth, the whole treatment regime starts with the atraumatic extraction itself, and that should not be overlooked.

Atraumatic extraction is a skill we should seek to develop, frequently we feel the need to deliver the tooth as quickly as possible due to patient anxiety or other constraints, but it is important to resist this when socket preservation is desirable.

When extracting anterior teeth a number of factors must be considered, not least the reason for the extraction, as that will have a bearing on how the extraction is carried out. A good quality pre-extraction radiograph is essential, the periapical view taken in a film holder being the view of choice. The film should be scrutinised to assess bone height mesially and distally, the presence of periapical pathology, root fracture (vertical or horizontal), evidence of previous apical surgery, or any other anomaly such as resorption.

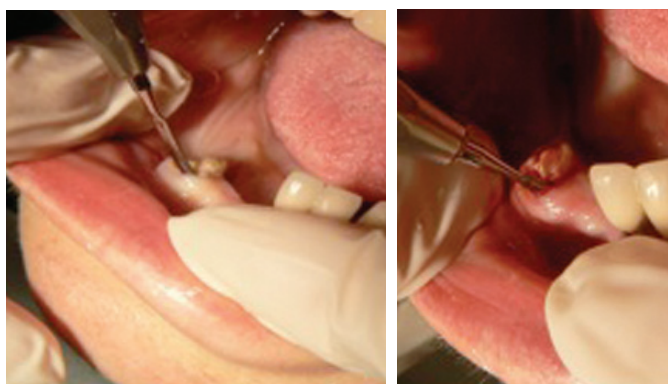
Surgical access at the front of the mouth is usually good, and incisors and canines are single rooted teeth which makes extraction more straightforward, however the buccal bone tends to be thin in this region, and is easily damaged or removed during the extraction process, this coupled with the high aesthetic demand commanded by this region makes extraction fraught with difficulty. Aesthetic zone implants are classified as "Advanced" in the SAC classification scale.



TOOTH LOSS AND ITS MANAGEMENT

The Extraction Process

The instrument of choice on starting the extraction process should be the periosteal elevator. The instrument is inserted into the gingival crevice, and used with axial pressure, hugging the root of the tooth. Careful side-to-side manipulation allows the instrument to progress gradually apically severing periodontal fibres as it progresses. Sharp luxators may perform a similar role once some expansion of the socket has taken place, but once again pressure should be applied apically to sever periodontal fibres. Remember a luxator is not an elevator, and using it as such may cause damage to the instrument or socket. The final delivery of the tooth from the socket should normally be with forceps, a rotational motion being the preferred, and least likely to destroy remaining bone.



Examining and measuring the extracted root, (particularly the distance from the amelo-cemental junction to the apex) is desirable, as in many cases it will give valuable information regarding the internal dimension of the socket itself and proximity of vital structures.

When extracting premolars the principles are similar, however these teeth tend to be oval in cross section, and multi-rooted, especially the first premolar which makes rotation movements inappropriate for the delivery of the root.

Molar teeth are invariably multi-rooted, in the lower two roots positioned mesially and distally, in the upper three positioned palatally, mesio-buccally and disto-buccally. The bone supporting teeth tends to become less dense further back in the mouth, and especially in the maxilla, so attempting to extract the tooth with the use of forceps is indicated. Firm apical pressure should be used to engage the tooth as far down its root surface as possible into the furcation, and gentle movements used to assess the bone's elasticity. If the tooth seems totally unwieldy, then sectioning the crown

should be considered at an early stage with each of the roots being delivered individually.

The socket should not be compressed following extraction of the tooth, this may damage the venerable buccal plate.

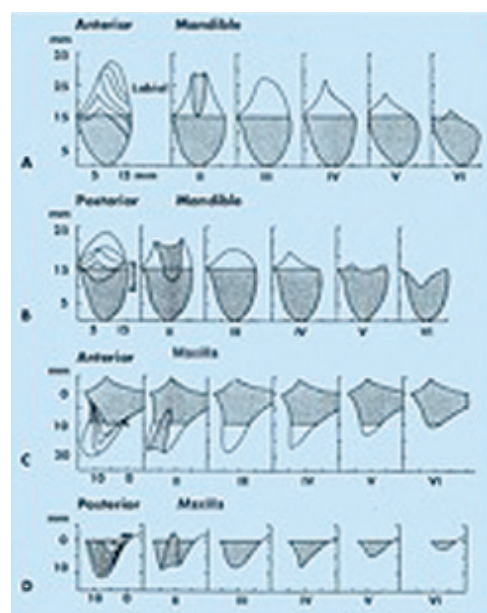
Post Extraction Healing

Following extraction, the bundle bone into which the periodontal fibres were once attached resorbs rapidly resulting in dimensional changes both in the hard and soft tissues surrounding the socket. As the buccal aspect of the socket is frequently very thin, often less than 1 mm in thickness this bone loss causes recession of the soft tissues.

Subsequently as bone height continues to reduce, the very thin buccal plate disappears more quickly, causing the socket to contract towards the lingual/palatal aspect, bringing about a loss in width, away from the facial aspect, this process was described by Cawood and Howell in 1991. This happens

relatively quickly following extraction, but is dependant on the thickness of the bone, the degree of trauma at the time of extraction and host factors specific to the individual.

It is for this reason that careful consideration must be given to the timing of implant placement, delaying too long may bring about unnecessary bone loss due to remodelling, yet too early placement may be compromised by inability to obtain stability of the implant in the socket, and the unpredictability of the healing process. Evidence also suggests that if the buccal bone is missing or damaged during the extraction process, placement of an immediate implant may not be an optimum solution. Socket augmentation with bone regenerative materials is indicated in 3 or 2 walled defects in which case implant placement is deferred approximately 12 weeks to allow the socket to regenerate first. Therefore socket size and morphology is one of the key factors that influence the decision making with respect to the timing of implant placement following tooth extraction.



Reproduced by kind permission of Munksgaard International Publishers Ltd, Copenhagen, Denmark. From Cawood J I, Howell R A, *Int J Oral and Maxillofac Surg* 1991; 20: 75

THE TIMING OF IMPLANT PLACEMENTS

An implant can be placed either in a fresh extraction socket at the time of tooth removal or later in native alveolous.

Time since extraction	Surgical description	Clinical properties
Zero	Immediate placement	No post-extraction healing of bone or soft tissue
4 to 8 weeks	Early (or delayed immediate) placement	Significant soft tissue healing, but little new bone
12 to 16 weeks	Delayed placement	Significant soft tissue healing, and significant bone healing
6 months or over	Late placement	Fully healed site

Immediate Implant Placement in Fresh Extraction Sockets

Implanting directly into an extraction socket (immediate placement) is appealing for many reasons. Post extraction healing and osseointegration occur simultaneously, surgical procedures minimised, and the reduced surgery time makes it a cost effective treatment modality. Some report better bone height maintenance in these cases, but that remains controversial.

Possible disadvantages of immediate implant placement include difficulty in obtaining primary stability of the implant, the presence of residual infection causing peri-implant infection (peri-implantitis), the space between the implant and the socket wall which may require grafting, all add to the unpredictability of the healing process making good aesthetic outcome impossible to guarantee, especially in surgeons with limited experience. Immediate placement is considered to be a “complex” procedure in the SAC classification.

Immediate implantations: (Araujo et al 2012)

- Can lead to high implant survival rates
- May be associated with a high risk for mucosal recession

Risk factors for the development of mucosal recession around immediate implants: (Araujo et al 2012)

- (i) Smoking
- (ii) Presence of a thin buccal bone plate (i.e., <1 mm thick)
- (iii) Presence of a thin soft tissue biotype
- (iv) Buccal implant position

Delayed Immediate or Delayed Implantations

Delayed immediate (early) and delayed placements have the disadvantage that the treatment is more protracted compared with immediate placements. However delaying the implantation allows for soft tissue coverage over the socket, which in return makes primary wound closure and graft containment easier. Deferral of implant placement also allows any pre-existing area of infection to subside. Thus, for many implant dentists this is the preferred method of implantation following tooth removal.

Late placement means overall treatment times are longer, however when preparing recipient sites in healed bone, the osteotomy may be positioned optimally in 3-D in all directions; mesio/distally, and oro/palatally. This is frequently the timing of choice for multi-rooted sites, allowing the implant to be placed centrally in the available space, by preparation of a single osteotomy where previously two or more root sockets existed. Late placement is also indicated when the tooth has been chronically infected or the socket requires substantial regeneration using the Guided Bone Regeneration or socket augmentation techniques.

Late placement implant placement into healed sites, not in the aesthetic zone is usually classified as “Straightforward” in the SAC classification scale, and are frequently the most suitable cases for a clinician new to implant treatment.

Socket Augmentation and Ridge Preservation Techniques

After dental extraction, wound healing typically results in dimensional changes in alveolar ridge morphology, compromising ideal implant replacement as well as dental aesthetics. The systematic reviews demonstrate that the alveolar ridge undergoes a mean horizontal reduction in width of 3.8 mm and a mean vertical reduction in height of 1.24 mm within 6 months after tooth extraction.

Ridge preservation (socket augmentation) vs ridge augmentation:

Ridge preservation = preserving the ridge volume that existed at the time of extraction

Ridge augmentation = increasing the ridge volume beyond the skeletal envelope existed at the time of extraction

Alterations in alveolar ridge morphology after tooth loss can be mitigated by socket augmentation procedures.

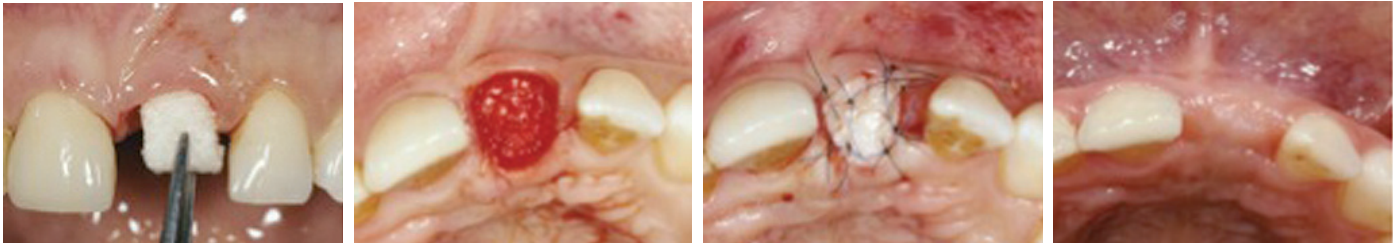
The techniques aimed at ridge preservation (or socket augmentation) involve two different approaches:

- i) Maintaining the ridge profile
- ii) Enlarging the ridge profile (Hammerle et al, 2012)

THE TIMING OF IMPLANT PLACEMENTS

The images below show application of a volume of xenograph/collagen regenerative materials within an extraction socket.

Insertion to the level of the crestal bone margin. Covering the socket with a soft tissue graft. Good soft tissue situation 6 weeks postoperatively allows for implant placement.



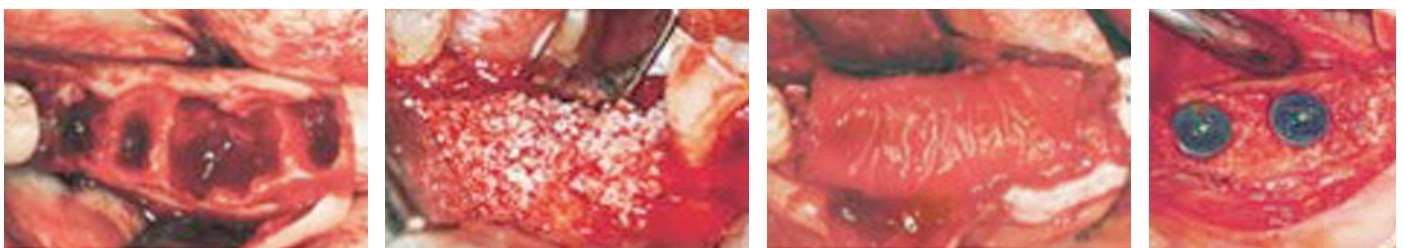Socket augmentation (also known as ridge preservation) reduces the amount of bone shrinkage that occurs as a result of disuse atrophy and bone remodelling that occurs after tooth removal. This technique involves packing bone regenerative materials into the extraction socket/s and covering with a cell occlusive resorbable membrane to prevent soft tissue ingress into the healing site. The cell occlusive membrane shown here is a natural collagen of porcine origin. Soft tissue is prevented from ingress into the extraction socket, allowing bone formation and maturation to occur within the socket. The socket augmentation technique works well with a variety of synthetic or natural products including xenografts.



Table: Indications for ridge preservation at the time of tooth extraction: (Araujo et al 2012)

- Maintenance of the existing soft and hard tissue envelope
- Maintenance of a stable ridge volume for optimising functional and aesthetic outcomes of implant treatment
- Simplification of treatment procedures subsequent to the ridge preservation

A healing period of 3 to 6 months is typically allowed for bone maturation to occur, prior to placement of implant fixtures. When multiple sockets are involved and a larger area of ridge is involved, this is referred to “ridge preservation”.



Images provided courtesy of Geistlich

DENTAL IMPLANT SURGERY

Dental implantology is a restoratively guided discipline with a significant oral surgical component. As implant dentistry is often an elective procedure, it should be meticulously planned and executed to ensure the highest probability of success both functionally and aesthetically with minimum morbidity and discomfort for the patient and the minimum risk of damage to vital structures. Most importantly implant treatment should not jeopardise or restrict patients future dental treatment needs.

Successful implant surgery should follow the sound principles of oral surgery. It is convenient to divide this into phases and events.

Surgical Planning

Surgical planning follows on directly from restorative planning which starts with a mock up or diagnostic wax-up of the dentition to determine the ideal restorative situation. The three-dimensional analysis will allow the practitioner to see where implants must be placed in order to support the planned prosthesis optimally.

Surgical planning takes into account the following considerations, and every step of the surgical procedure is envisioned prior to the operation:

- Patient suitability - is the patient medically fit for surgery? Has the patient's GP or specialist been consulted?
- How complex is this case according to the SAC classification?
- Is the surgery within the skill levels of the treating practitioner? Should this case be treated by a team of clinicians experienced in treating more complex cases both surgically and restoratively?
- Access - is there sufficient intraoral access to allow the planned surgery to take place?
- Is hard or soft tissue grafting required to allow the optimal placement of the planned implants?
- How will the patient be provisioned during these stages?
- Are any vital structures at risk during surgery such as the inferior dental nerve, mental nerve, infra orbital nerve, lingual nerve or floor of the mouth? Does the patient's medical condition require in-patient care under specialist supervision?
- Are modified or special surgical protocols required for the placement of the planned implants?
- Is the provisional restoration able to protect or at least not harm the surgical site?
- Is oral or intravenous sedation likely to be required? If so a dedicated suitable second professional should be attending.

- Has the patient been fully educated and informed of the alternatives, advantages, disadvantages, limitations, risks and the prognosis of the proposed treatment? Does the patient have an itemised cost estimate?
- Have all the facts surrounding the nature and long-term expectancy of the treatment and alternatives been transparently disclosed to the patient for a rational decision to be made? Would informed consent be valid?
- Is there a contingency plan in place to deal with intra or post operative complications?
- Is the required long-term maintenance and monitoring programme feasible or practical in this case?

Preparation for Surgery

Preoperative preparation includes getting the patient ready for surgery, both physically and mentally.

The patient should be medically fit for surgery. Medically compromised patients may require further assessment in consultation with their GPs or specialists. Their preoperative diet should be adequate with supplements given as required, especially in patients that appear underweight or have selective diets. They should be instructed on what to do with their normal medication. On no account should they be instructed to discontinue medication prescribed by another clinician or their GP without consultation.

All primary dental disease should be eliminated and treated before embarking on implant treatment. The mouth should be rendered plaque-free with a timely preoperative hygienist visit and there should be no overt inflammation or infection present at the time of implant surgery. Exceptions may be where a tooth with a chronic apical abscess or a vertical root fracture is to be electively removed at the time of implant placement.

Preoperative medication should be given in good time to be effective. Non-steroidal anti-inflammatory drugs and antimicrobials work best as preventive drugs and should be administered with sufficient time for them to be absorbed before surgery commences.

Patients with beards or moustaches should ideally be asked to shave the day before surgery to reduce the bacterial count within the field of surgery.

The postoperative symptoms are normally similar to that is experienced after tooth extraction for the majority of straightforward cases. In more complex cases, there may be significant postoperative symptoms from the operation site or the provisional restorations.

DENTAL IMPLANT SURGERY

The patient should be aware of what to expect both during and after surgery and the level of the discomfort that they are likely to experience. The patient should consent to treatment after the above information has been discussed both verbally and in writing and are provided with clear post operative instructions including appropriate pain management. Use of antibiotics post operatively may not always be necessary in straight-forward cases in healthy patients but is considered essential in bone grafting or in advanced/complex cases.

Requirements for Basic Implant Surgery

A dentist providing implant treatment should have received adequate postgraduate training. The standards governing the training and provision of implant treatment have been published (by the FGDP/GDC) and are discussed in this document below. The GDC has advised that *“Placing dental implants is a surgical procedure which should only be carried out by a dentist who is competent to do so as a result of suitable training. Such training would normally be a post-graduate or masters training course in implant dentistry.”*

The guidelines further state that:

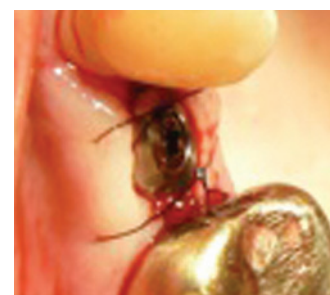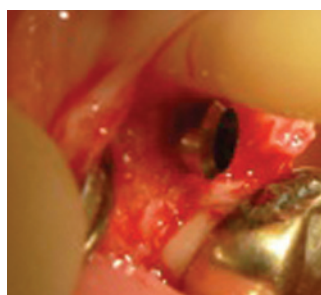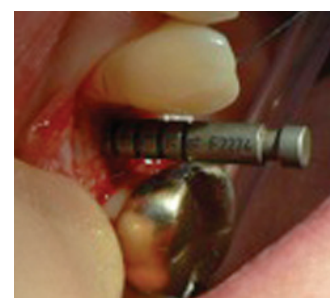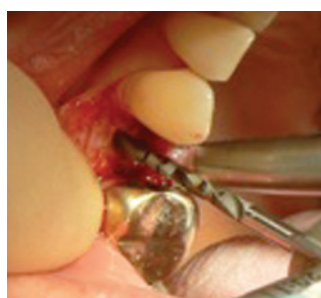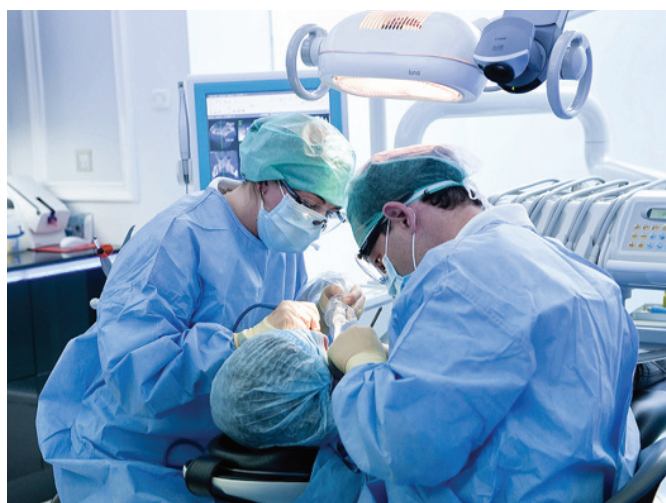“The clinician must take an evidence-informed and patient-centred approach to their choice of techniques and materials, and be satisfied that the manufacturer of materials is sufficiently stable and of adequate stature to be able to provide component parts for the foreseeable future. The clinician should also take responsibility for assessing the effects any implant feature may have on the surrounding tissues.”

It is taken for granted that suitable quality surgical armamentarium and equipment including resuscitation equipment must be available. The clinician should also ensure that they have suitable indemnity cover for implant procedures at the level of complexity they operate.

Dentists undertaking basic implant surgery should have mastered the following:

- **Aseptic Surgical Technique:** cross infection control is critical not only to prevent cross contamination but also to reduce the bacterial count within the surgical field. This would normally involve the use of full sterile set of surgical drapes and gowns for the operating team and the patient. Preoperative use of mouth-washes and skin disinfection are considered good practice. Sterilisation and safe storage of large number of surgical instruments that may be needed for each case should conform to current policies and guidelines.
- **Pain and Anxiety Control:** implant surgery can be prolonged. The administration of appropriate type and dosage of local anaesthesia is crucial to ensure that the surgical field is anaesthetised adequately for the duration of the operation without overdosing. Use of intravenous sedation for prolonged cases might be advisable.

- **Atraumatic Surgical Technique:** this includes the ability to cut suitable flap designs for adequate and atraumatic access to the implantation site
- **Knowledge of Surgical Anatomy and Vital Structures:** this includes the ability to recognise different grades of bone quality when preparing the osteotomy to optimise the primary stability and positioning of the implant
- Wound closure, tension free suturing and post-operative management of symptoms and complications including pain control
- Provision of appropriate temporary/provisional restorations



ADVANCED IMPLANT SURGERY, BONE AND SOFT TISSUE AUGMENTATION

Advanced implant surgery may include regenerative procedures such as guided bone regeneration (GBR), bone condensation, ridge splitting, particulate grafting, autogenous block grafting, sinus augmentation, connective tissue grafting and further special methods such as inferior dental nerve lateralisation and distraction osteogenesis.

In recent years, clinical and technological advances in implant surgery have increased the available treatment options for the reconstruction of a wide variety of dental defects predictably and safely. All dental clinicians should make themselves

familiar with the availability of these techniques and materials. The relative advantages, disadvantages, risks and implications of these treatment options, materials and techniques should be carefully considered and discussed with the patient before determining the most optimum treatment for individual requirements of each patient. Although any one clinician may not possess a wide variety of advanced surgical and restorative skills, he/she must be aware of their general availability and scope and be ready to recommend them as part of comprehensive dental care, if necessary, delivered by suitably experienced different clinicians in a team approach.

Advanced implantology techniques:

Bone condensation	The compaction of soft bone using an osteotome to improve bone quality and therefore implant primary stability
Ridge splitting	The division of a narrow alveolar ridge into two plates to effectively widen the bone width
Particulate grafting - 1 stage	The use of autogenous bone chips or proprietary particles of bone to augment bone volume at the same time as implant placement. Adequate bone should exist for stabilisation of the implant and the grafting should predominantly be within the envelope of the deficient ridge. A membrane should also be used to separate the bone from the soft tissue compartments and to confine the particulate graft in situ. This technique is referred to as Guided Bone Regeneration.
Particulate grafting - 2 stage	The use of autogenous chips or proprietary particles of bone to augment bone volume prior to placement of the implant. A membrane should also be used to separate the bone from the soft tissue compartments. This can be used when there is inadequate bone volume for primary implant stability. A period of healing is allowed for the newly regenerated bone to mature before subsequent implant placement.
Block grafting	The use of an autogenous block of bone harvested intra or extra-orally is fixed to the deficient alveolar ridge to augment width, height or both. This type of grafting requires advanced surgical skills and training. Particulate grafting and a barrier membrane can also be used concurrently.
Sinus augmentation (osteotome or closed sinus lift technique) (also referred to as Summer's Technique)	The elevation of the sinus membrane through a vertical osteotomy within the implant site and placement of a particulate graft to increase bone volume for placement of implants. Can be carried out concurrently or as a separate procedure prior to implant placement.
Sinus augmentation (lateral window)	The elevation of the sinus membrane using a lateral window (similar to Caldwell Luc technique) and placement of a block of bone or regenerative materials to augment the bone volume across the whole floor of the sinus. This is indicated when the residual bone height is less than a few millimetres. Can be carried out concurrently or as a separate procedure prior to implant placement depending on the actual height of the residual bone below the sinus floor.
Inferior dental nerve (IAN) lateralisation	Mobilisation and lateral repositioning of the IAN to accommodate implants in the posterior mandible. This technique allows the placement of the implant fixtures in the posterior mandible where the residual bone height above the IAN is less than adequate.
Distraction osteogenesis	The use of a dedicated surgical device to move a separated but vascularised section of bone from the alveolus and migrate it to a desired position to increase bone volume. The space vacated by the controlled migration of the separated section will fill with bone under the intact periosteum. This technique has not found widespread use due to limited availability of devices suitable for 3-D bone regeneration.
Soft tissue augmentations	Use of soft tissue grafts to improve the quality and quantity of the peri-implant soft tissues may be indicated. These can be of: Autogenic (e.g. palatal connective tissue or mucosal grafts), allogenic or collagen of animal origin.

SURGICAL AFTER-CARE AND COMPLICATIONS

The patient is provided with comprehensive post-operative instructions, suitable medication for pain control and prevention of infection and have a 24-hour emergency helpline directly to the surgeon.

Even if resorbable sutures have been used, patients should be routinely reviewed at between one to two weeks after surgery for suture removal. High standards of oral hygiene and general health should be maintained for the duration of the healing period.

Printed post-operative instructions and post-operative sundries such as ice packs, gauze and medication must be given to the patient prior to them leaving the surgery.

Patients should ideally be sent home under the guardianship of a responsible adult preferably by private transport.

When the implants have been placed in the anterior mandible the patient should be warned regarding the risk of severe bleeding and swelling of the floor of the mouth occurring as this could potentially compromise the airway. This would indicate a serious surgical emergency and hospitalisation.

Post-operative complications to look for:

- Infection
- Bleeding
- Pain
- Swelling and bruising
- Suture granuloma
- Wound dehiscence and break down
- Membrane exposures
- Altered sensation or numbness to teeth, gum, lip etc.
- Devitalisation of adjacent teeth

Damage to Inferior Alveolar Nerve

This can occur as a result of implant placement in close proximity of the IAN and particularly in case of poor surgical planning and/or technique. Any report of paraesthesia or altered sensation occurring to the teeth, lip or the gum should be investigated urgently and the signs and symptoms should be recorded. Early referral to an oral surgeon would be an advantage.

The ADI has developed and published a set of Guidelines on the prevention and management of inferior alveolar nerve damage. Please see the ADI website for more details

Signs and symptoms of nerve injury:

- Pain
- Numbness or tingly sensation

Investigations

- Pin prick, 2 point discrimination, light touch and hot and cold tests
- An appropriate radiograph including CT scan if necessary
- A photograph documenting the size of the affected area

Outcome

- Majority will fully recover
- A small minority will not recover
- Debilitating and lasting pain could be the most significant feature that might be difficult to manage

Treatment

After assessment and diagnosis of the nature of the injury and the likelihood of spontaneous recovery of nerve function consideration should be given to:

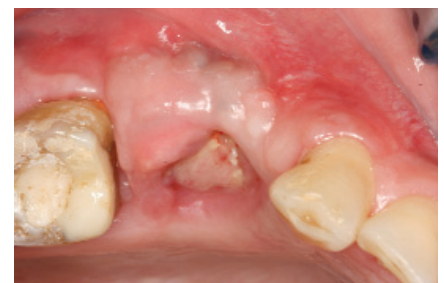- a) decompression of the nerve injury by backing the implant out a few turns or complete removal
- b) Medication: corticosteroids and other drugs
- c) Microsurgical nerve repair on referral

Jaw Fractures

These are very rare. However, unexplained and prolonged source of pain after implant placement should be investigated to exclude the possibility of jaw fracture particularly in the mandible.

Premature Membrane Exposure

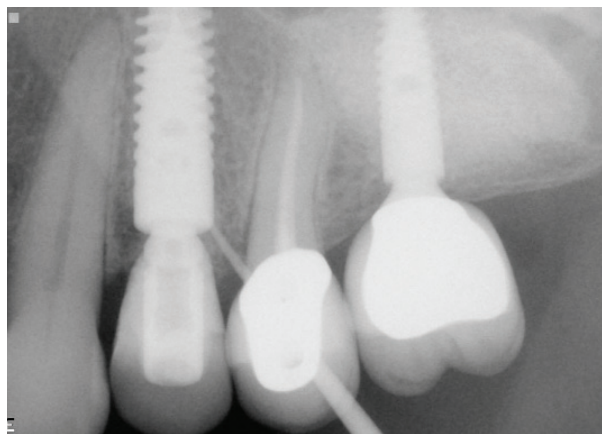
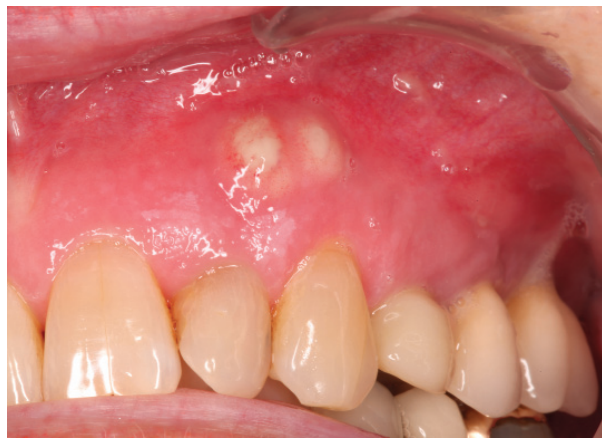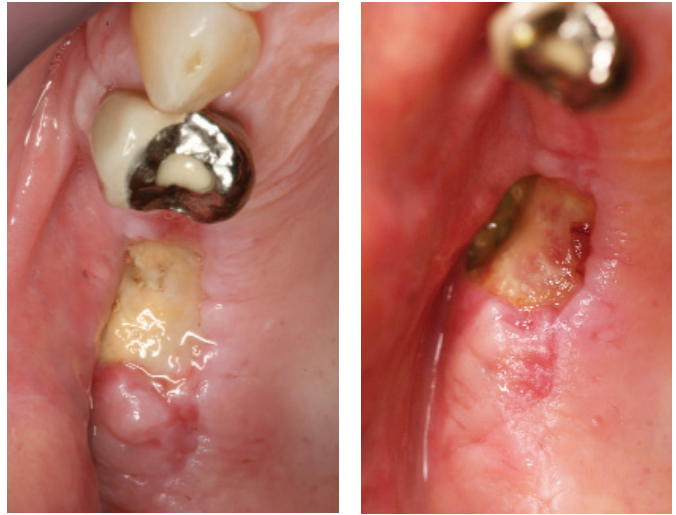This could occur after implant placements and/or GBR. Higher incidence of membrane exposure has been reported with the use of non-resorbable or highly cross-linked collagen membranes, as these do not readily integrate with the wound through rapid transmembraneous vascularisation. In these cases, the removal of the exposed membrane is advocated to reduce the risk of infection. With resorbable membranes such as natural collagen, wound infection is not a common feature even if the membrane becomes exposed during healing, as these natural products have been shown to become rapidly vascularised through transmembraneous infiltration of the microcirculation. Use of chlorhexidine mouthwash is recommended in case of wound breakdown.



SURGICAL AFTER-CARE AND COMPLICATIONS

Infection

Localised infection at an implant site can arise from poor surgical technique, necrosis or contamination due to failure to reduce the bacterial count in the surgical field. Smoking, uncontrolled diabetes and periodontal disease are risk factors. Very rarely severe or persistent infections could arise for no apparent reason. There is some evidence that this may be due to activation of dormant foci of infections within the bone, which are impossible to identify in radiographs. Osteomyelitis, although very rare has been reported after implant surgery. Patients presenting with post-operative infection should be investigated and followed up carefully to prevent the spread of infection systemically. Use of repeated doses of antibiotics blindly should be strongly discouraged.



Postoperative Pain

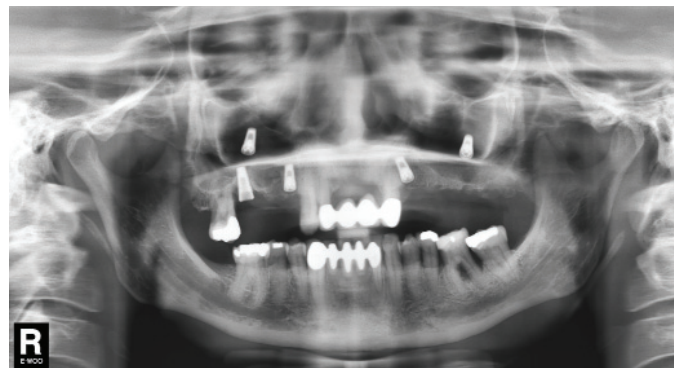
Clinical studies have shown that majority of patient's report only mild discomfort and pain after straightforward implant placement surgery. This is normally controlled with paracetamol 500mg or ibuprofen 400mg. Prolonged or severe pain is unusual and therefore would warrant further investigations and diagnosis.

Maxillary Sinus Complications

Maxillary sinus can be involved either as part of the planned surgical procedure (closed or open sinus lift/grafting) simultaneously or in 2-stage procedure when placing implants. In healthy individuals the success of bone regenerative procedures within the maxillary sinus cavity has been demonstrated to be safe and reliable. Severe complications, however can arise due to poor surgical technique, infections and wound break down. Patient factors such as pre-existing sinus pathology, immunosuppression, medication, uncontrolled diabetes and periodontal disease also increase the risk of complications. An infected sinus graft should be treated rapidly, preferably a referral to a specialist or more experienced clinician.

Displacement of Implants into Maxillary Sinuses

This is being reported with increasing frequency. Retrieval of the implant preferably by endoscopic surgery is indicated to prevent the migration of the implant or damage to the sinus cavity.



IMPLANT RESTORATION

The decision on when to restore the implants (including immediate loading or provisionalisation) should be based on the bone quality and quantity at surgery, the stability of the implants and the likely healing period envisaged for the bone and soft tissues. Furthermore, other factors such as the occlusion and presence of parafunctional habits must be taken into account when treatment planning.

Implant restoration can be broadly divided into two main restorative disciplines; those that are patient-removable and those that are fixed.

A) REMOVABLE IMPLANT OVERDENTURES

Most industrialised countries are experiencing a rapid decline in edentulism. However, tooth loss increases with age, so the number of edentulous patients within society will continue to increase for several decades because of the increase in mean age.

Total tooth loss is a serious life event. Becoming edentulous renders an individual as disabled and many patients report that they subsequently experience lowered self-confidence and poor self-image. Complete dentures have been the traditional standard of care for edentulous patients for more than a century. Many denture wearers are able to wear a maxillary complete denture without problems but most struggle to eat with the complete mandibular denture because of its inherent mobility. In the past few decades, culture changes have resulted in heightened patient expectations. Many 'older' patients now find it unacceptable to consider having conventional complete dentures due to inferior comfort and function.

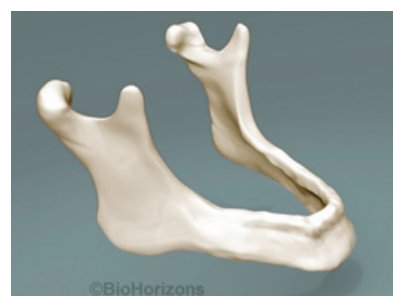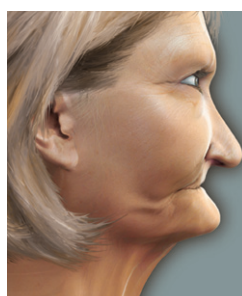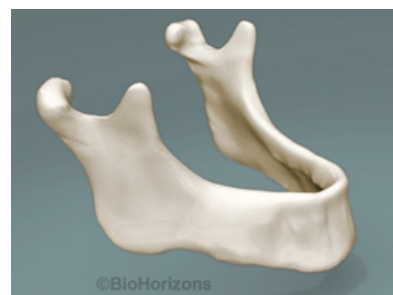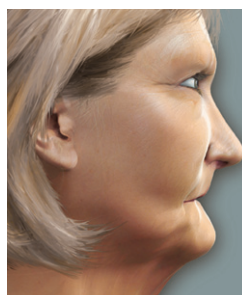
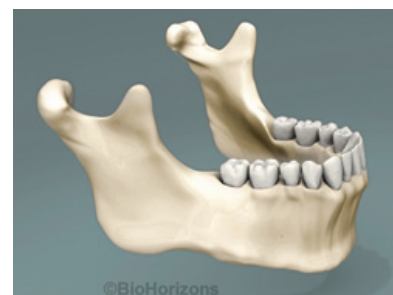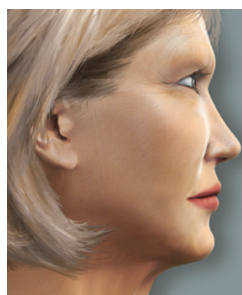Many scientific studies have been carried out over the past decade to determine the benefit of the mandibular two-implant overdenture. The results are significant enough to propose that a mandibular implant overdenture, rather than the conventional denture, should be regarded as the first treatment option in the management of the edentulous mandible. The Mc Gill consensus statement on overdentures states that "a two implant overdenture should become the first choice of treatment for the edentulous mandible."

This conclusion has later been supported by the York consensus statement (see ADI Guidance Paper on Overdentures). In addition to the functional and psychological benefits to patients, there is good evidence that implant placement in the edentulous jaw will promote bone preservation and prevent continued bone resorption.

A removable implant overdenture treatment is identified as a viable and first line treatment option. Patients may present as totally edentulous or edentulous in one arch and opposing a natural dentition in the other.

What Happens to the Facial Support following Total Tooth Loss?

We have already described the process of physiological alveolar bone resorption following tooth loss, however when the resorption becomes excessive, skeletal support for the facial tissues is lost resulting in a 'collapsed' facial appearance of ageing. Patients who have been edentulous since an early age often present with an 'overaged' appearance.



Courtesy of Biohorizons

When anterior teeth are lost, horizontal bone resorption is twice as great as vertical bone loss. This means that the optimal position of the prosthetic tooth replacement is considerably anterior to the position of the dental implants within the bone of the anterior maxilla. This can potentially cause a cantilever effect in function. In the edentulous maxilla implant distribution around the arch is important.

IMPLANT RESTORATION

When restoring edentulous patients the treatment choices are:

Conventional Complete Dentures

Dentures have never been a good substitute for natural teeth. A conventional denture is reliant on the mucoperiosteum for support and retention. The dentures are resting on mucosal tissue and can be easily dislodged by the strong forces of the adjacent muscles. This is a particular issue in the mandible where instability of the denture in function is a common complaint. A stable conventional denture is one which moves little during function. Patients who are 'denture tolerant' often have developed good muscular control and this, rather than the surface fit results in the successful wear of the prosthesis. Fundamental principles of complete prosthetic design apply whether a conventional or implant based treatment is being considered.

Removable Implant Overdenture

A removable implant overdenture is a prosthesis which is removable by the patient and is supported or retained by dental implants. The prosthesis has to be removed for the purpose of cleaning the implants. Patients who have been edentulous for a number of years are often 'denture tolerant' and seek treatment to stabilise their progressively loosening dentures rather than always demand the fixed option. These patients invariably present with hard and soft tissue deficit where the aesthetic benefit of acrylic flanges in restoring facial support is crucial to a successful treatment outcome. Facial support and dental aesthetics are more readily restored in this group of patients with implant overdentures rather than a fixed prosthesis.

Screw Hybrid Retained Prosthesis

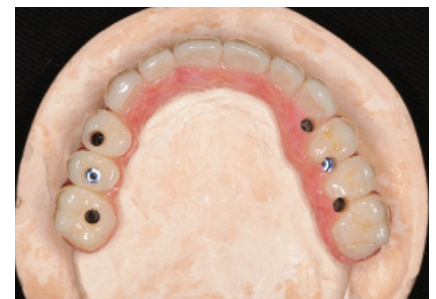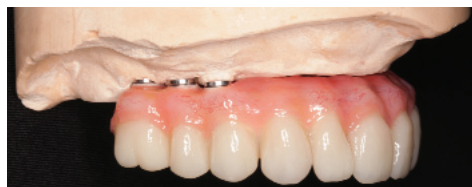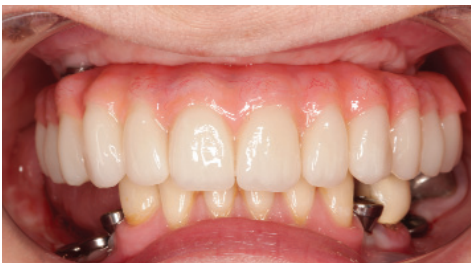The hybrid implant restoration is a design which combines the acrylic flange component of a conventional denture with a screw retained restoration on dental implants. There is a metal framework either made from titanium or a cast precious metal and acrylic prosthetic teeth are used to complete the restoration. This reconstruction is non-removable by the

patient but, being screw retained, is removable by the clinician. A hybrid implant restoration is typically supported by 4 to 6 implants depending on the available bone volume. The potential disadvantage of this design is the difficulty in access for cleaning. Aesthetics might be more difficult to achieve compared with a removable overdenture as spaces must be incorporated for adequate plaque control and oral hygiene purposes. In the maxilla, phonetics may also be an issue in some patients as the air can escape between the implants and the flange of the hybrid prosthesis. More-over, the acrylic teeth suffer from rapid differential wear or fractures during function. Although, given the operator removability repairs are usually easy, patients should be made aware of these disadvantages and should make provisions for repairs or remedial treatment in years to come.

Fixed Restoration

With a fixed full arch implant restoration, it is often difficult to create a restored facial appearance in terms of facial profile and lip support in patients who present with extensive skeletal bone atrophy. Such cases may also preclude the placement of a sufficient number of implants to allow a fixed prosthesis to be considered. An implant overdenture will always require fewer implants than a fixed restoration in the edentulous jaw.

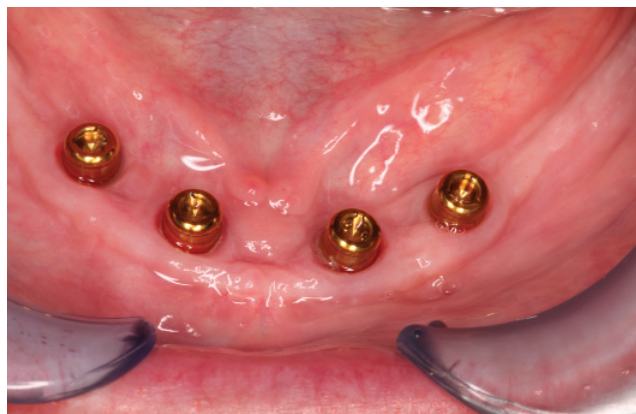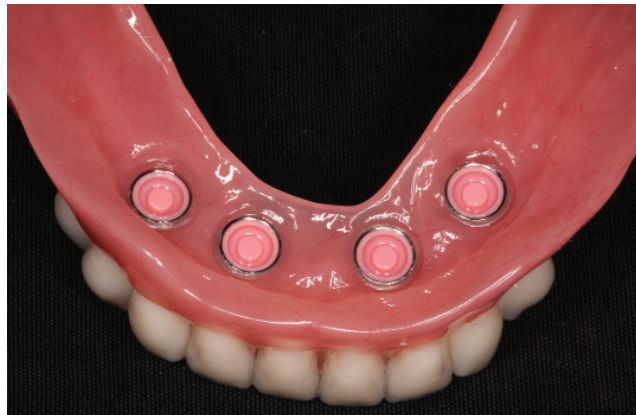Hybrid and fixed restorations are considered by the patient to be non-removable. Implant overdentures are removable and are generally a very successful treatment. They have high implant survival compared with fixed prosthodontics, high patient satisfaction levels, relatively simple treatment protocols and treatment time that is comparable to conventional prosthodontics. Initial treatment costs are low compared with fixed restorations and various attachment systems can be used to restore the implants. Clinical studies, however have shown that overdentures may require more maintenance in the long term including periodic relines to compensate for continued bone shrinkage that occurs under the mucosa that partially supports the prostheses in function. Failure to do so could result in overloading of implants or retentive devices.



IMPLANT RESTORATION

Classification of the type of overdenture treatment:

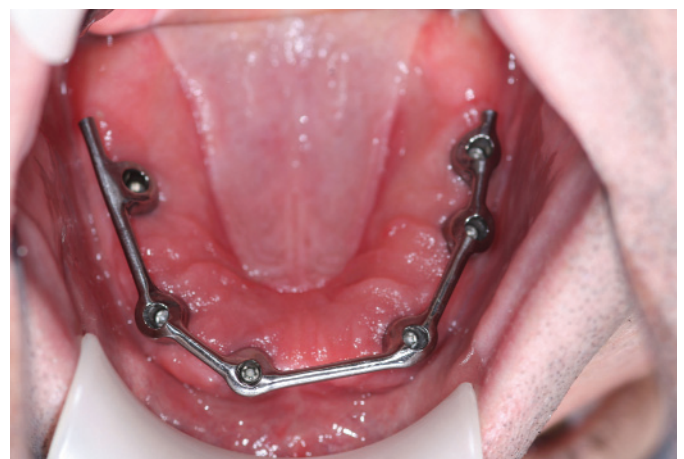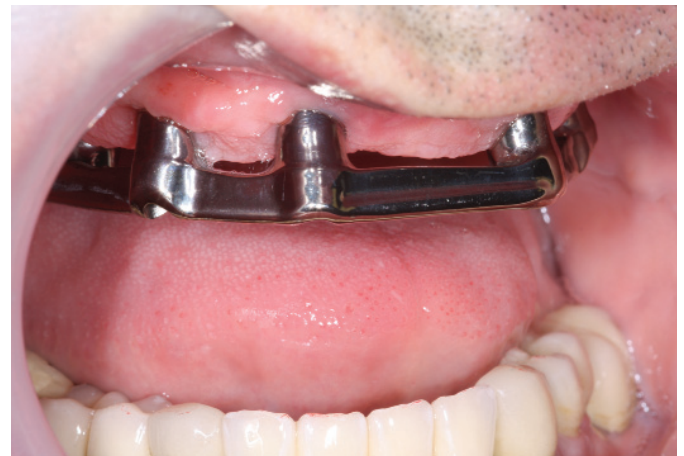Mainly tissue supported - implant overdenture where two individual attachments are used. The overdenture is mainly tissue-borne. The attachments give retention to the prosthesis. The overdenture base needs maximum tissue coverage like a conventional denture. In eating, the ridge receives masticatory forces. In the mandible a minimum of 2 and in the maxilla a minimum of 4 implants are indicated for this type of an overdenture. Relining of the denture bearing area will still be required. This is often the case with two mandibular implants in the lower canine sites. The tissue supported implant overdenture is useful in cases where the presenting problem is that of denture movement. Dentists who provide long-term monitoring and maintenance to the overdenture patient should review the need for a relines periodically.



Tissue-implant supported - two implants and a resilient bar attachment is needed. The base of the prosthesis still needs extensive tissue coverage but during function the implants and attachment assembly receive most of the forces with some being absorbed by the supporting tissue. This type of prosthesis is mostly implant supported and usually requires a minimum of 3 implants in the mandible and 4 in the maxilla.

Fully implant supported - this requires a minimum of four implants in the mandible and 4 to 6 in the maxilla. During mastication, the attachment assembly transfers all the masticatory forces to the supporting implants. The consequence of this is that minimal flange and tissue coverage is needed since the prosthesis is fully implant-borne.

The totally implant supported overdenture not only retains the removable prosthesis but also provides support for chewing function. This type of implant overdenture is particularly appropriate for patients who present with considerable functional difficulty and pain while functioning on their complete dentures. There are some disadvantages of implant borne overdentures, these include a higher cost due to more implants and components. Furthermore a minimum of 12mm intraocclusal space (from the head of the implant to the opposing occlusion) is needed to accommodate the retentive bar or framework.



IMPLANT RESTORATION

Supporting and Retaining Overdentures

Before a decision can be made regarding choice of retaining assembly, clear information is required on the available vertical space.

This is the distance between upper and lower ridge as measured on the mounted articulated casts. This tells the clinician how much available prosthetic space there is to accommodate the prosthesis baseplate as well as the chosen attachments. Failure to plan this accurately can lead to great difficulty in the treatment delivery at a later prosthetic stage.

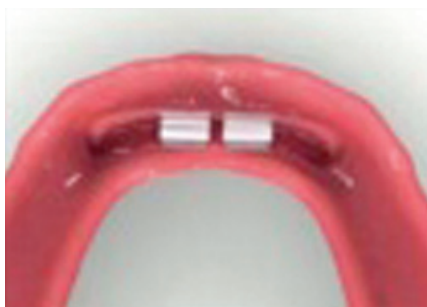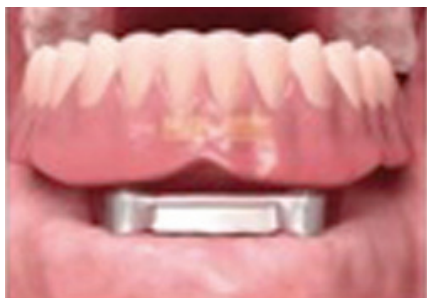The components available for retaining overdentures are:

- Bars with clips
- Studs such as ball anchor devices
- Locators with plastic retentive elements
- Milled cylinders or frames
- Magnets

Bars With Clips

The removable overdenture bar assembly offers the advantages of a conventional removable prosthesis with the stability and retention of a fixed reconstruction. Splinting dental implants together by means of a bar will also distribute the occlusal forces more favourably during function and this can contribute to improved long-term success.

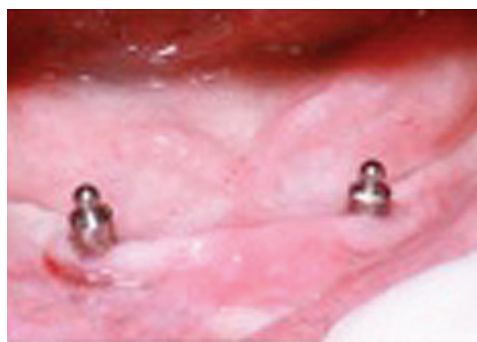Bar construction is either by traditional cast technique by the laboratory using prefabricated bars and soldered onto abutments or by a lost wax technique. The alternative to this is to construct a CAD/CAM bar which has been shown to have a more passive



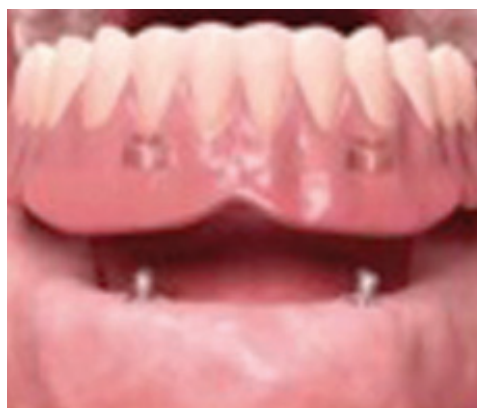fit. Constructed in milled titanium the bar is lighter and cheaper than cast gold bars. The CAD/CAM design utilises a matrix of the desired tooth set up during the construction process ensuring that the end shape and position of the bar is dedicated to the desired optimal tooth position. This gives the clinician confidence that once the bar is located onto the implants in the mouth, the prosthetic teeth can be accommodated within the neutral zone both in the vertical and horizontal dimensions.

Stud Connectors

Stud attachments are available for connections with all mainstream implant systems. The retaining 'stud' component has a dedicated housing which is cured (with acrylic) within the overdenture base. The connector is available with a



variety of 'collar' depths allowing for the thickness of soft tissue between the level of the implant and the soft tissue emergence of the implant to the mouth.

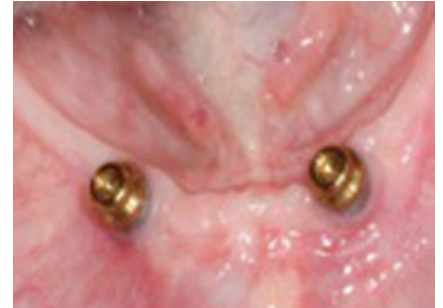
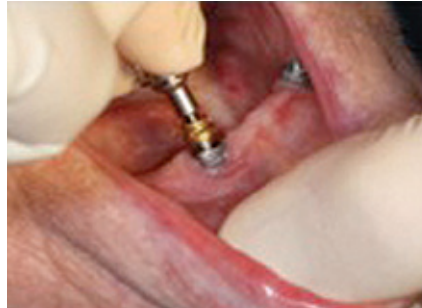

Stud connectors tend to allow rotation of the heels of the prosthesis, have a tendency to wear, are unforgiving to non parallel implants, are expensive to replace, provide less retentive force than alternatives and the matrices (within the denture) require frequent changes.



IMPLANT RESTORATION

Locator Attachments



The locator attachments (Zest Anchor Ltd) are designed for use with implant retained overdentures. The locator attachment is made of a titanium alloy with a nickel titanium coating and is available for most implant systems.



The following features outline many of the advantages in the use of these attachments in retaining and stabilising an implant retained overdenture:

Self-aligning - means that the locator attachment helps the patient to position their overdenture by gauging the prosthesis into the optimal position over the attachment. This also ensures that the locator abutments are not damaged due to repeated insertion of the prosthesis.

Low attachment profile - presents the considerable advantage in the choice of this abutment. Where there is limited available vertical space between either the edentulous ridges or between one edentulous ridge and the incisal edge of the opposing teeth, the locator attachment assembly (abutment plus patrix within the denture base) can be as low as 2.5 mm in total. Taking up minimal vertical space provides a considerable advantage over other attachment options.

Dual retention design - is unique to this attachment. The locator attachment has a combination of inside retention on the top of the abutment and a circumferential retention groove on the outer surface also. This increases the surface area to facilitate this retention of the overdenture this design also improves the longevity of the components.

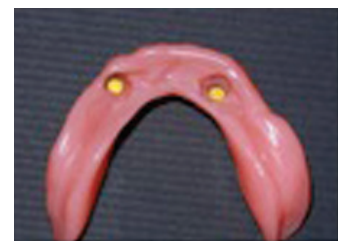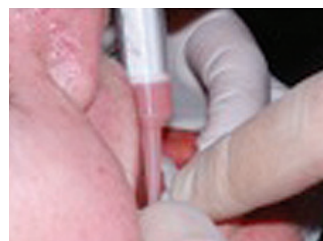Choice of retention strength - the patrix components (within the denture base) carries a replaceable nylon insert which is colour coded according to the retentive strength it can provide. The clinician can therefore select the degree of retention tailored to the needs of the patient. Where locator attachments are being used on parallel implants (10 to 20°) then an alternative nylon insert is placed within the patrix (green, orange, red).

Pivoting denture matrix - the design of the patrix within the locator assembly provides a resilient connection for an overdenture but at the same time will not result in a loss of retention.

Non-parallel implants - that have been placed in a divergent position can be restored with the locator abutment in the construction of the implant retained over denture. Divergences between 10 and 20° (40° between implants) can be tolerated when using the extended range replacement inserts.

Locators have generally replaced the use of other retention devices in recent years as they are affordable, simple to use, resist tipping and the maintenance stage is straightforward.

There are two ways to utilise locators. The direct technique involves final processing of the overdenture by the laboratory and pickup of the aluminium cap by the clinician at the chairside using a self-curing acrylic resin.



The indirect technique involves ensuring that all aspects of the trial tooth setup are optimal in the mouth. A fixture level impression is recorded by the clinician and the technician selects the optimal locator height on a soft tissue model. The final processing of retaining assembly within the denture base is then completed by the laboratory technician when the final acrylic processing of the overdenture is undertaken. The final prosthesis is then returned to the clinician for fit.

Milled Cylinders

These are technically difficult to use as the implants need to be perfectly parallel and they are also expensive. They do have the advantage providing a rigid connection and being very retentive.

IMPLANT RESTORATION

Magnets

Magnets tend to corrode over time. There is a loss of magnetism and they are not very retentive. Due to these factors magnets are rarely used nowadays.

Factors Affecting the Attachment Mechanism

As it has been emphasised, systematic planning of optimal tooth position is essential before embarking on any implant surgery. Once the desired tooth set up is established, the decision as to the attachment assembly choice for the implant overdenture can be made.

Establishing optimal tooth position helps to determine:

- Optimal implant position and allows surgical guide construction
- Available vertical space for retaining components
- Patient acceptance of desired final result

B) FIXED IMPLANT PROSTHETICS

The surgical placement of dental implants is a very predictable process and has been covered in a previous section. The osseointegration of dental implants has revolutionised dentistry, allowing the replacement of missing or damaged teeth with the option of a fixed solution, negating the need for preparation of any remaining natural teeth. A fixed restorative result is highly desirable as it allows security in function (speech and perception), improved masticatory efficiency and occlusal support together with psychosocial improvement. The direct support of a fixed restoration by implants allows a decreased volume of the prosthesis, in particular, a fixed maxillary solution can be provided without extensive palatal coverage.

Design features:

Passive Fit

When providing a fixed prosthesis, it is essential that all components of the restoration fit passively together. Failure to provide a passive fit may result in adverse pressures on implant, abutment or crown leading to mechanical or biological complications. Passivity is ensured by utilising verification techniques in each step of the construction of the restoration and can be confirmed if required using radiographic imaging to visualise the implant/abutment/crown interface.

Hygienic and Aesthetic Design

The design of a fixed implant solution must ensure adequate strength in function and aesthetics whilst allowing ease of cleansing to ensure that the ability to clean and maintain the supporting implant(s) is not diminished.

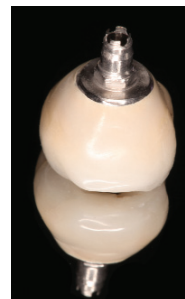Screw or Cement Retained

A fixed solution can be achieved by either fixing the prosthetic directly to the implant head using a screw for retention, or can be achieved by cementing the final prosthetic on to an abutment, which, in turn, has been screwed to the implant. There are advantages and disadvantages to each of these methods, which are of relevance in specific cases. Whilst screw retained fixed solutions offer greater retrievability which is important to allow repair and maintenance as required over time, the screw access channels can be deemed detrimental to aesthetics - implant orientation is of paramount importance to ensure the screw access point can be placed palatal to the incisal edge anteriorly or on the occlusal plane posteriorly. Screw retention requires placement of components to a specific force (torque) to ensure their adequate retention in function. Screw access channels require to be covered using a suitable protective material after seating of a screw retained restoration. Cement retention can provide a more desirable aesthetic outcome, however, it can be difficult to ensure that any excess cement is removed from a sub-gingival abutment margin and such excess cement if left in situ can be responsible for the initiation of peri-implant disease. Retrievability can be an issue in cement retention and although some clinicians will advocate the use of a temporary cement for a definitive restoration, even then, its removal if required can be very difficult assuming that the restoration has been properly manufactured.

Indications

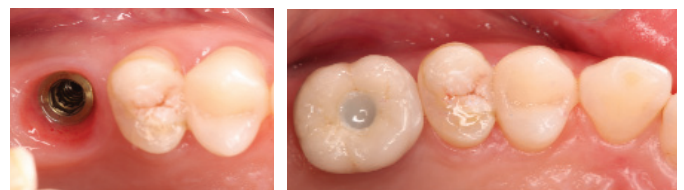
Fixed implant restorations can be provided in all manner of situations, including single teeth, short span bridges, medium span bridges or full arch restorations, all of which will be discussed in turn. The restorations themselves can be made from many and varied restorative materials chosen for their specific case benefits in terms of strength in function, aesthetics or a combination of both.

Fixed Implant Restoration – Single Tooth



A fixed solution can be provided on an implant to replace a single missing tooth. This solution can either be screw retained or cement retained but both solutions start by adequately recording the position of the implant with a specific impression.

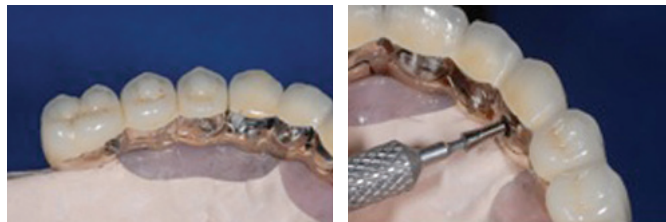A screw retained fixed solution requires the production of a one-piece abutment and crown which can be screwed into place to provide the final solution.



IMPLANT RESTORATION

A cement-retained solution requires the production of an abutment initially. Abutments can be of the pre-fabricated type, which can be placed and used with or without alteration depending upon the position of the implant. Abutments can also be specifically manufactured using either a cast wax casting technique or CAD-CAM technology. Such abutments can be manufactured using many and varied materials including titanium, gold and zirconium. Regardless of the abutment type, its angulation and morphology must allow the passive but retentive fit of the definitive crown. Following its construction, the abutment is retained in the implant generally using screw retention, however, some systems will use only frictional retention. Once in place, the definitive crown will be cemented into place.

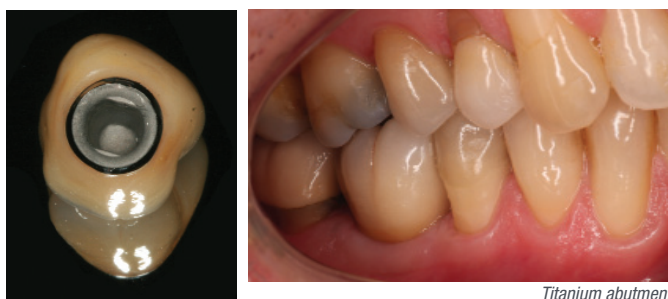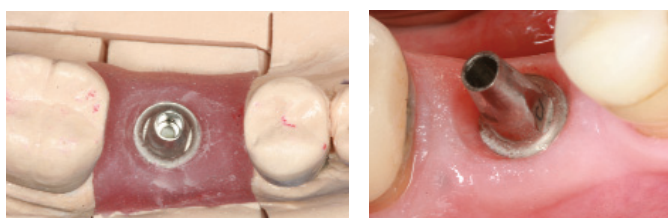
A screw-retained superstructure can be constructed to fit passively to multiple implants and retained via screws. This solution offers good retrievability particularly in longer span bridges.



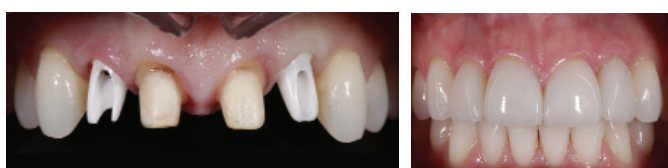
If the long axes of multiple implants are not relatively coincident, the screw retention may not be feasible. In such cases, abutments would be made for each individual implant and constructed in such a manner that angular correction between deviant implants occurs. This would allow the construction of a bridge, which would be cemented onto the abutments ensuring a passive fit.

Fixed Implant Restoration – Full Arch Bridge

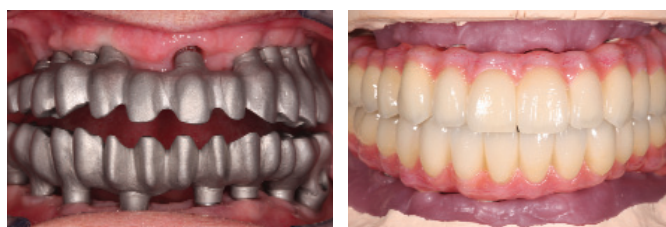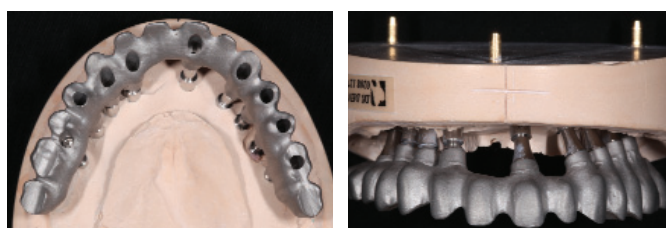
Multiple implants can be used to provide a solution where all teeth in an arch are missing. Again, serious consideration must be given to the number of implants required to retain the proposed fixed solution, ensuring longevity in function. With an increasing number of implants, the angulation of each implant is of paramount importance in determining the final solution, which should ideally be screw retained.



Titanium abutment



Zirconia abutment

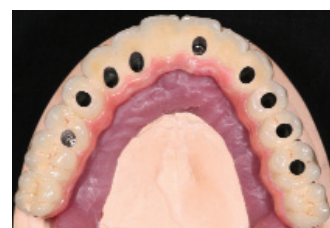

Fixed Implant Restoration – Short and Medium Span Bridges

Multiple implants can be used to provide a solution where more than one tooth is missing. There is an important decision to be made regarding the number of implants which will be used to support a specific design fixed solution when more than one tooth is missing.

This is dependent upon many case-specific factors, all of which must be adequately considered during case assessment and planning. In order for more than one implant to retain a screw retained fixed solution, the implants require to be adequately placed such that their long axes display only minimal deviation. This being the case, an adequate record of the position of the implants is taken with a specific impression, which can then be verified to confirm accuracy.

Where the angulation of implants will not allow simple screw retention, angled abutments can be used to correct deviations, allowing the passive fit of a final screw retained full arch solution.



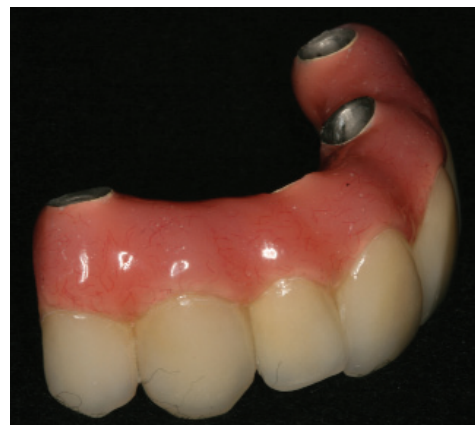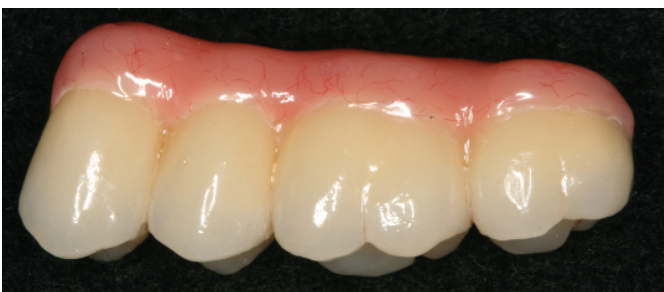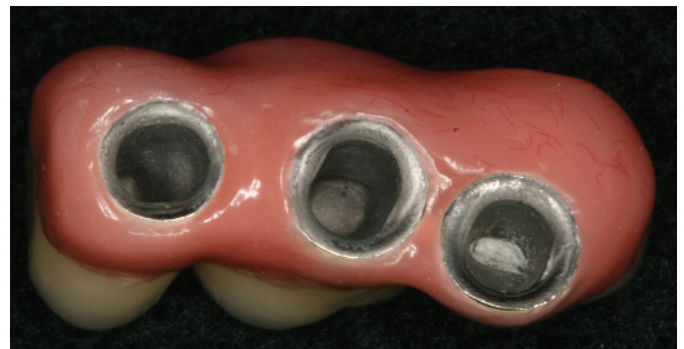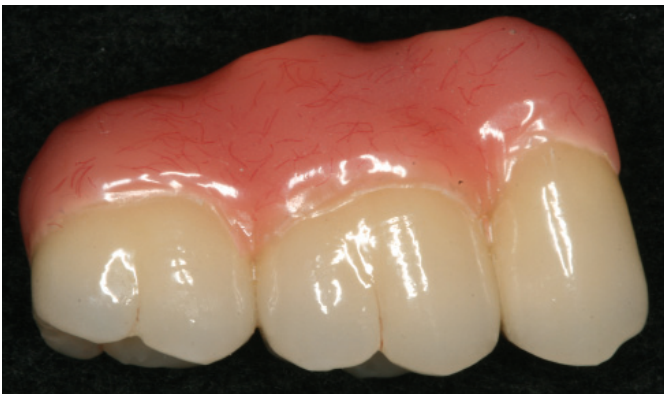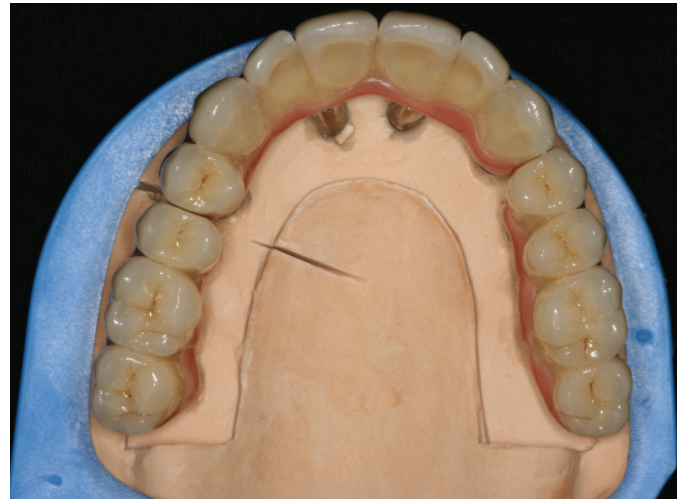
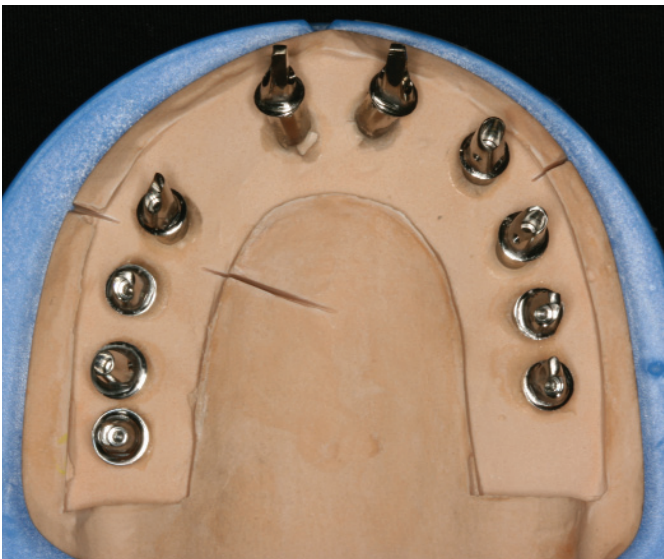
IMPLANT RESTORATION

Fixed Implant Restoration – Full Arch Hybrid Bridge

In some cases, the provision of a screw retained full arch fixed solution is not possible. In these instances, it is possible to produce a fixed bridge structure with separate crowns in the areas where implant angulation is unfavourable.

This allows fabrication of a screw retained definitive solution onto which crowns can be cemented in areas where implant angulation requires unfavourable screw access holes. Whilst retrievability is not ideal in these cases, the individual crowns can be removed if required to allow access to the screw holes and replaced as individual units.

In cases where the hybrid bridge detailed above is unsuitable, and cement retention of a full arch fixed solution is required, the full arch solution can be cut into smaller sections which are then cemented into place. These smaller retained bridges have retrievability issues as previously described, however, in a full arch case, this design will allow smaller sections to be removed if required.



MAINTENANCE PHASE OF DENTAL IMPLANTS

Complications and Prognosis

The survival of implants in suitably selected patients is generally very high. Implants however do fail and can be lost for a variety of reasons. Scientific evidence suggests that the longevity of implants may not be superior to that of a diseased but well-restored natural dentition. A key factor for long-term implant survival is the quality of periodontal and implant maintenance.

Dental implant complications can be divided into two types:

a) Early complications

b) Late complications

Early implant failures usually arise from failure of the initial integration to take place during the biological healing phase. Poor surgical technique, inability to achieve primary fixation, inadvertent implant loading during the integration phase, infection and systemic conditions such as uncontrolled diabetes are some of the factors that could cause early implant loss.

Late failures are caused by one or both of the following two fundamental reasons:

a) **Biological failures:** caused by plaque-induced peri-implant disease. If untreated, the progressive crestal bone loss results in implant mobility.

b) **Mechanical failures:** caused by unfavourable loading conditions due to poor restorative design or failure to control occlusal interferences. Typically, mechanical failures are manifested by screw or abutment loosening or porcelain fractures. Implant fractures have also been reported but these tend to occur in reduced diameter implants.

Early failures are difficult to predict, measure or prevent. Late failures, on the other hand, can be identified and treated successfully if they are intercepted in the early stages of the disease process. In this respect, any clinician who accepts an implant patient for maintenance assumes significant responsibilities and duty of care for monitoring dental implants and the health of the peri-implant soft tissues. This requires a systematic recall programme of monitoring and maintenance.

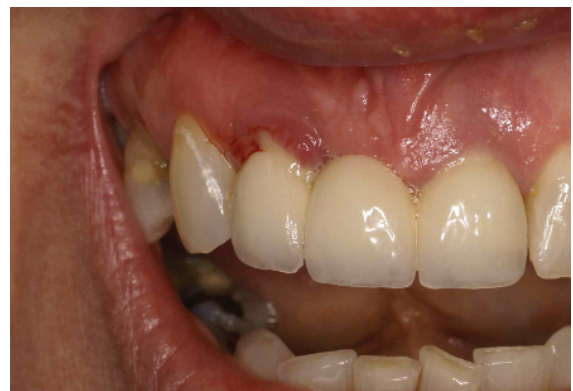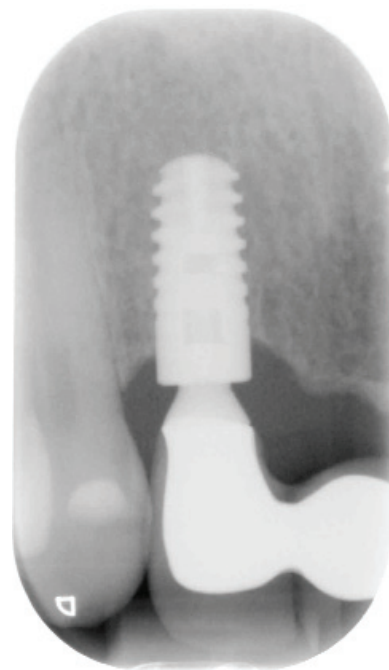
Recent surveys have shown that there appears to be contradictory advice on how best to monitor and maintain dental implants in function. This is surprising as the peri-implant disease is increasingly being shown to be common with an incidence rate ranging from 5% to 56%. Given that the current market is approximately 130,000 implants per year in the UK, this represents a large number of patients who might be affected by peri-implant disease annually.

"Recent cross-sectional studies suggest that peri-implantitis occurs in 28-56% of subjects". Professor Tord Berglundh ADI Focus Meeting 2010.

Evidently, the importance of a strategic approach to implant monitoring and maintenance is clear; this can be divided into the following areas:

- Reduction of risk factors
- Patient education and motivation
- Screening and surveillance
- Instrumentation and intervention

"There is no treatment for the failed implant!"



MAINTENANCE PHASE OF DENTAL IMPLANTS

REDUCING RISK FACTORS

Host Susceptibility

There is evidence to suggest that patients with history of periodontitis are not necessarily at risk of losing their implants prematurely, however they may be at a higher risk of developing long-term peri-implant bone loss compared with patients with no history of periodontal disease. A direct cause-effect relationship has been demonstrated between plaque and peri-implant disease with identical microflora being present around teeth and implants. Host response is modified by many factors including genetics, systemic conditions such as uncontrolled diabetes, medication including bisphosphonates, heavy smoking and immunosuppression. Higher the host susceptibility, the more meticulous the plaque control and maintenance should be. Identification and control of co-morbidities such as diabetes forms an essential part of management of these patients.

Prosthetic Design

As adequate oral hygiene and plaque control is one of the most fundamental factors influencing the longevity of dental implants, ideal prosthetic design should not impede the provision of optimum home care and professional maintenance.

There is also emerging evidence that overloading can potentiate plaque-induced peri-implant bone loss. Occlusal integration should therefore be planned and maintained meticulously to reduce the risk of overloading by minimising interferences and premature contacts. This applies to any future restorative treatment that could potentially alter the occlusal harmony.

Implant Design

Ligature-induced periodontitis in dogs found that the surface roughness of the implant may effect the susceptibility to peri-implant disease. However systematic reviews did not reveal significant difference in survival rates between different implant designs or surfaces.

Soft Tissue Quality and Quantity

Studies have also found that mechanically thick, keratinised and non-mobile mucosa is desirable for maintaining healthy peri-implant tissues. Soft issue grafting can therefore be indicated in patients who present with thin, non-keratinised and fragile mucosa which could be susceptible to mechanical trauma.

Patient Factors

Smoking, systemic disease, medication, osteoporosis and bone quality and density are some of the factors that could affect the long-term prognosis.

Motivation

Motivation is one of the most important factors that could affect the long-term outcome of implant treatment as it directly influences how well the implants are maintained in function. Dental professionals should therefore be actively involved in increasing patient education and motivation.

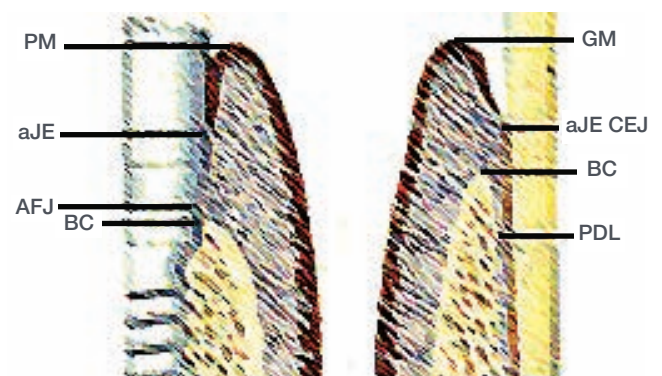
Screening and Surveillance

It is recommended to keep a log of implant cases. The best way to do this is to use the ADI Implant Logbook. There is a need to assess the implant for health on a regular basis, a sensible recall interval is every 6 months following a year of intense monitoring post restoration. It must be remembered that teeth and implants have different peri-implant tissues.

Tooth Versus Implant

Dental implants differ from natural teeth is a number of ways:

- The peri-implant tissue has less blood supply
- There are no transeptal or gingivodental fibres around implants
- There is a junctional epithelium attachment to the implant abutment
- There is no periodontal ligament associated with an implant, instead it is fused directly to the bone (osseointegration)
- The implant lacks sensory feedback of occlusal forces. Due to this, the monitoring of the occlusion, in particular carefully noting:
 - Screw loosening
 - Fracture of the prosthesis
 - Attrition
 - Redness, swelling, discomfort
 - Denture ulcers

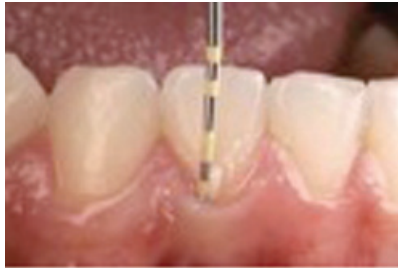

- PM - peri-implant soft tissue margin
- aJE - apical termination of junctional epithelium
- AFJ - abutment-fixture junction
- BC - marginal bone crest
- GM - gingival margin
- CEJ - cemento-enamel junction
- PDL - periodontal ligament

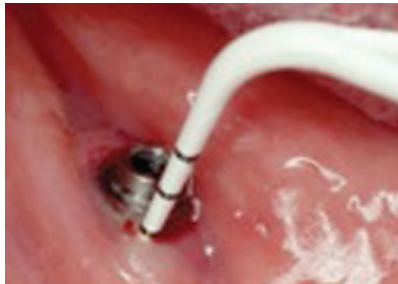MAINTENANCE PHASE OF DENTAL IMPLANTS

Peri-Implant Tissues

The soft tissue around an implant appears clinically similar to the tooth; however continuity of the mucosal epithelium is important to maintain a barrier and seal.



Probing implants must be done with care. A gentle probing force must be used so that the tip of the probe does not penetrate the junctional epithelium and connective tissue all the way to the bone. In healthy tissue, the probe will stop at the coronal level of the connective tissue. In the presence of inflammation, the probe tip may penetrate close to the bone.



The current literature suggests that probing should be carried out routinely to screen the implant for pathology. If any inflammation is present a radiograph is recommended to evaluate any bone loss.

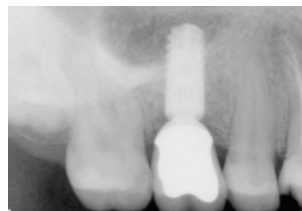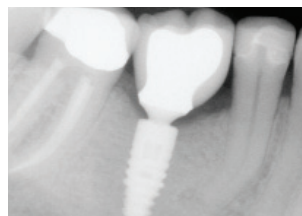
It needs to be highlighted that probing depths may differ around implants, due to the depth that the implant has been placed. Deeper probing depths are not necessarily pathological. Unless bleeding or pus, depth increasing with time (compared to baseline), radiographic evidence of bone loss (2mm of loss is acceptable in the first year, and 0.2mm each year after).

Probing must be recorded at every recall interval and from a reproducible reference point.

Radiographic Interval

It is recommended that implants are assessed radiographically:

- At fit of the prosthesis
- At 1 year
- Biannually thereafter
- If any signs for symptoms
- Using a periapical
- Using a reproducible technique.



Examination

It suggested that the following are assessed at a 6 monthly recall:

- Dental chart
- Oral hygiene
- Peri-implant tissue: tone, colour and texture
- Inflammation: gently squeeze the peri-implant tissues assessing erythema, edema bleeding and exudate
- Pathology: probe implant sulcus lightly, bleeding on probing including the absence of and depths
- Radiograph if pathology is present and every 24 months to check for bone level changes
- Mobility
- Prosthesis: check for prosthesis stability

Implant Instrumentation and Debridement

Removal of deposits on the implant should be accomplished with instruments that are implant-safe. The implant should only be debrided if it is clinically necessary.

The dentist/dental hygienist can effectively debride the implant with gentle working strokes and light pressure using a titanium or metal handscaler. Instruments that are not recommended include standard ultrasonic and sonic instruments.

Recall Interval

Establish a recall interval for the patient. This would normally be 6 monthly assessment by a dentist. If you are concerned regarding oral hygiene, complications, or the patient is compromised, a monthly recall is recommended.

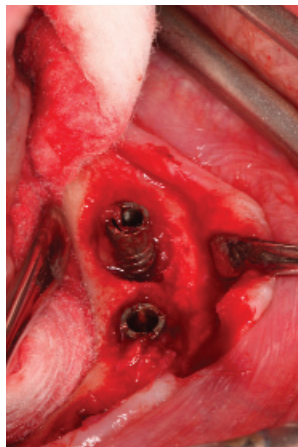
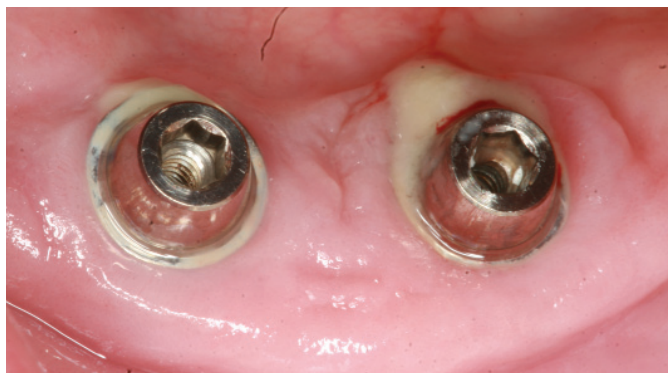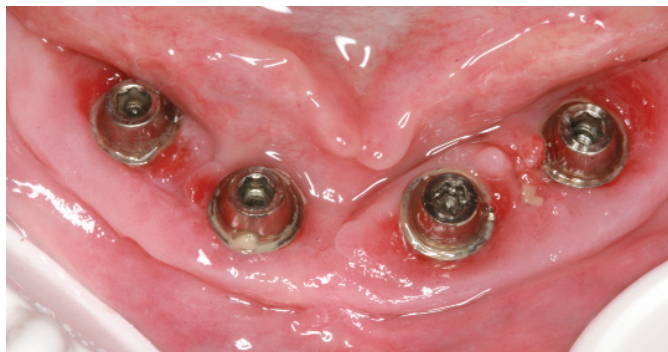TREATING PERI-IMPLANT DISEASE

Aetiology and Clinical Features of Peri-implant Mucositis

Peri-implant mucositis is inflammation located to the soft tissues only. Signs and symptoms of the disease include bleeding on probing, increased pocket depth, swelling, discharge or suppuration and radiographs show no evidence of crestal bone loss. Peri-implant mucositis is reversible whereas peri-implantitis is not. The ADI has developed and published useful Guidelines on the Diagnosis and Management of peri-implant disease. Please see the ADI website for more details.

Aetiology and Clinical Features of Peri-implantitis

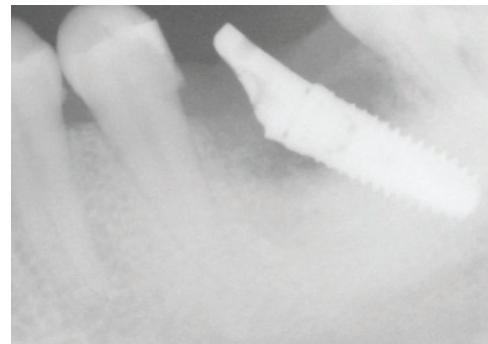
Peri-implantitis is an inflammatory process affecting the tissues around an osseointegrated implant in function, resulting in the loss of supporting bone. The clinical features of this process may involve clinical signs of inflammation, but the diagnostic feature is the crestal bone loss.



Radiological evaluation is a useful tool in the assessment of peri-implantitis, but due to projection artefacts often underestimates the size of the defect. False negatives are also a problem as the radiographs can only show the mesial and distal bone but not the labial or lingual bone surfaces that are masked by the implant body.

It is therefore recommended that peri-implant probing is essential in the diagnosis of this condition. A probing force of 0.25N is

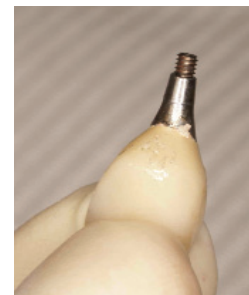
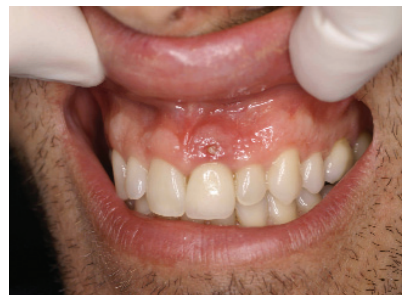recommended. As we have discussed, probing around an implant allows the early detection of peri-implantitis which is vital in both its treatment and mitigating



further disease progression, it is however a technique sensitive investigation and care must be taken not to probe the implant shoulder. A key diagnostic feature of inflammation is bleeding on light probing.

Mobility is a terminal stage of peri-implantitis, and careful diagnosis is required as other causes of implant mobility are more common, in particular mobility or fracture of the superstructure. Pain is not normally a feature and frequently the patient is unaware of any problems.

Peri-implantitis is an infectious disease and therefore it is important in the differential diagnosis to exclude other causes of inflammation, the most common being retained cement, or cementitis.



It is also imperative not to confuse the normal physiological remodelling of bone due to surgical trauma which can occur for up to one year post placement, with this disease process.

There is considerable evidence that the aetiology is of a bacterial nature, and the majority of studies suggest that teeth and implants share risk factors, the most important being poor oral hygiene and smoking.

The bacteria typically have a low pathogenicity without invasive properties; they are not aggressive and produce low chain polymer substances that contribute to the biofilm. The infections tend to chronic, evade the hosts defence mechanisms and tend to be localised to a specific site not becoming systemic.

A dental implant is a type 3 medical device as it crosses the epithelial barrier into a non-sterile environment. Exposure to micro-organisms is therefore inevitable and colonisation of the sterile implants surface will occur. Normal implant flora' is compatible with health, however ecological factors that promote an unwanted shift in resident flora are to be avoided.

TREATING PERI-IMPLANT DISEASE

PERIODONTITIS AND PERI-IMPLANTITIS

One Cause For Two Diseases?

The arguments for this concept include the common microbial and clinical features, along with common risk factors (smoking, genetic factors and poor oral hygiene), and the higher incidence of peri-implantitis in patients with a history of periodontal disease. The counter argument is that peri-implantitis is also seen in patients with no history of periodontal disease, and the disease is defined by the site rather than the pathogen.

Diagnosis

It is suggested that the following scheme is adopted, it must be noted however, that the most important clinical feature in the diagnosis of peri-implantitis is the peri-implant probing depths.

- 1) Is there suppuration?
- 2) Are there clinical signs of inflammation?
- 3) Are there pocket depths >3mm?

If the answers to the above are all no, this indicates health. If any are yes then proceed to question 4.

- 4) Does the pocket extend more than 3mm beyond the implant shoulder?
- 5) Is there bone loss?
- 6) Is there a plausible cause other than peri-implantitis?
- 7) Is the pocket deeper than 5mm?

Treatment

The most important aspect of the treatment is to clean the implant surface. The ability to be able to do this depends on the implant type. Rough surface implants cannot be cleaned effectively with mechanical methods alone. It is important to realise that this is not a 'disease of the bone'. The process starts in the connective tissue, on the smooth surface with a biofilm, then the rough surface is affected. The associated bone loss is a result of this process.

There have been six systematic reviews analysing the treatment of peri-implant disease. These studies all present many approaches and protocols for the treatment of peri-implant disease, however they present little evidence to support one particular method. The unpredictable nature and limited long-term reports of success would explain the varied approaches.

The literature suggests a number of key objectives in the treatment of peri-implant disease. These are to remove aetiological factors, infection control, debridement and decontamination of the implant surface and regeneration of the lost support.

The literature also suggests that there are essentially two approaches to treating peri-implant disease; surgical and non-surgical. Both of these approaches may be supplemented with treatment to remove aetiological factors, oral rinses, and systemic antibiotics.

The ADI have developed and published a comprehensive set of guidelines, together with simple-to-follow algorithms for the treatment of peri-implant disease. These can be found on the ADI website.

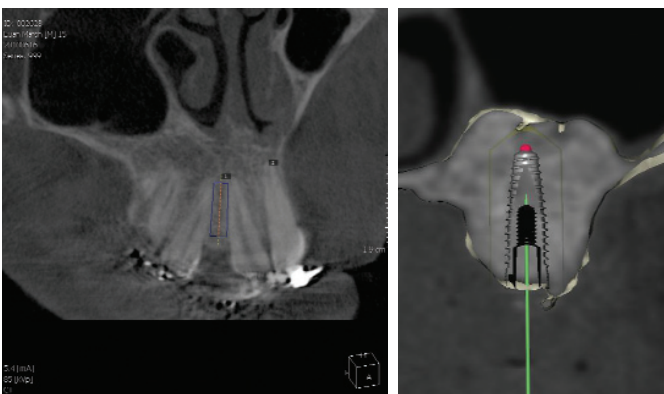
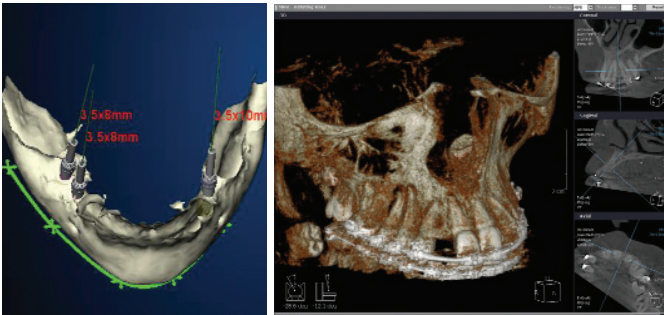
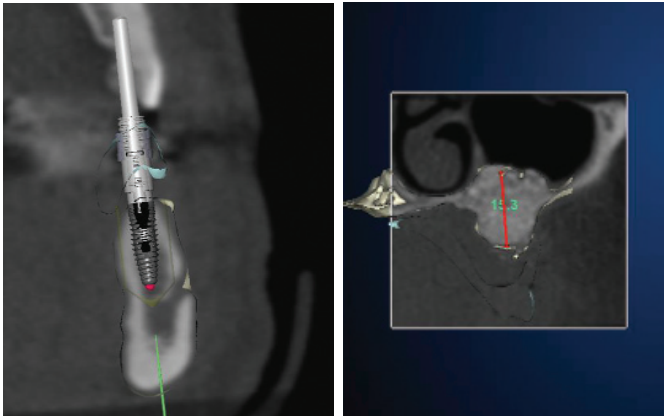
0)	Implant failure, fracture primary complications (within 6 months of placement)	Explanation or 2
1)	Cementitis, infection from a foreign body	Debridement and disinfection
2)	Moderate peri-implantitis, probing depth <4mm bone loss <2mm	Debridement and disinfection and systemic antibiotics
3)	Advanced peri-implantitis, probing depths >5mm bone loss >2mm	Surgical access. Debridement and disinfection and systemic antibiotics.

“It is often in the best interests of the patient if they are referred back to the implantologist if the GDP suspects peri-implant disease.”

THE LATEST DEVELOPMENTS IN DENTAL IMPLANTOLOGY

Computer technology is impacting dramatically in dentistry and this is particularly the case in dental implantology. The move from analogue to digital has the potential to make treatment planning more sophisticated, surgery safer and produce higher quality restorations.

Virtual Treatment Planning and Guided Surgery

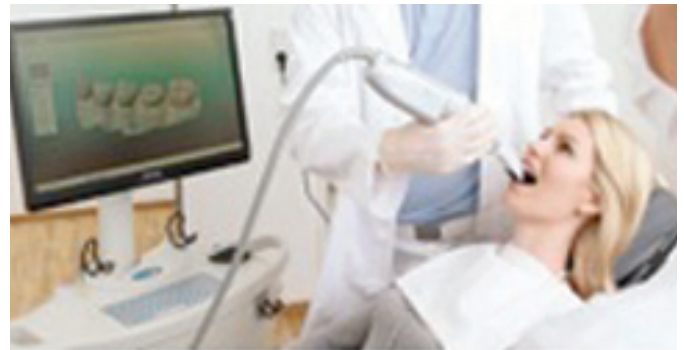

Cone beam computerised tomography (CBCT) uses a cone shaped x-ray beam to provide three-dimensional images of the cranio-facial structures at a significantly reduced radiation dose than traditional CT. The raw CBCT images are stored as dicom file that can be imported into dental implantology

treatment-planning software. Mandibular and maxillary anatomy can be studied three-dimensionally and implant placement planned with consideration to bone quality, availability and the presence of important anatomical structures. A radiographic stent produced from a diagnostic mock-up of the final restoration is worn for the scan to verify bone availability in the areas where restorations are required. The software is then used in the production of a surgical stent that guides the positioning of the implants during surgery. Surgical placement is highly predictable and can often be carried out flaplessly. The pre-planning and control of implant positioning also facilitates the pre-operative manufacture of very accurate provisional restorations that can be fitted immediately after placement of the implants.

Digital Impression Techniques

Digital impression systems use an intra-oral scanner to capture an image of a tooth (or teeth) preparation or an implant. This image is then electronically transferred to a manufacturing facility that fabricates a working, articulated model. This model is then sent to the lab of choice. From this model, a multitude of different restorations can be fabricated — crowns, bridges, inlays/onlays, veneers and implant abutments are all possible. The laboratory liaises with the manufacturing facility in designing the restoration. A coping or abutment is normally produced using a computerised milling process at the manufacturing centre then forwarded to the laboratory for final porcelain layering.



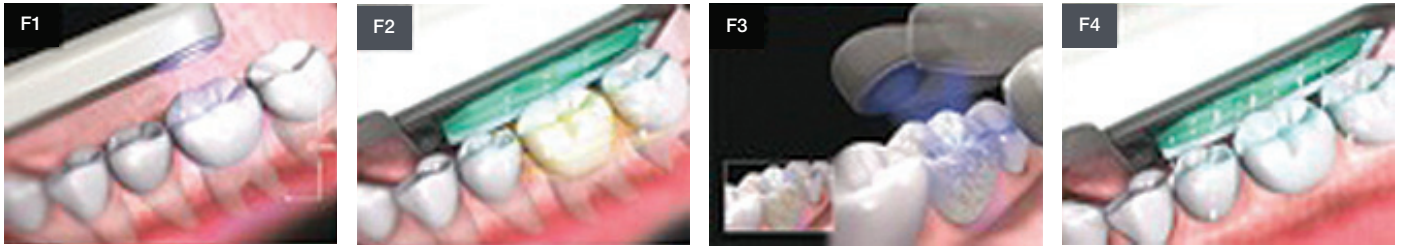
Intra-Oral Scanner

Computer-Aided Manufacture of Restorations

Even without a digital impression laboratories are able to manufacture restorations using computer-aided design and computer-aided manufacture (CAD-CAM). Conventional impressions are cast as usual but the analogue models are scanned in the laboratory. The digital information is used to design and construct a wide range of restorations as described above. The bespoke design and industrial manufacture process increase the accuracy of fit of restorations whilst at the same time often providing greater durability.

THE LATEST DEVELOPMENTS IN DENTAL IMPLANTOLOGY

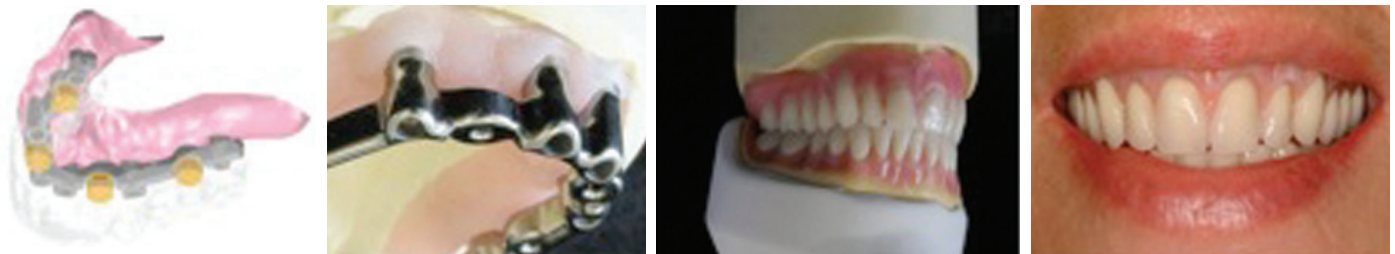Intra-Oral Scanner



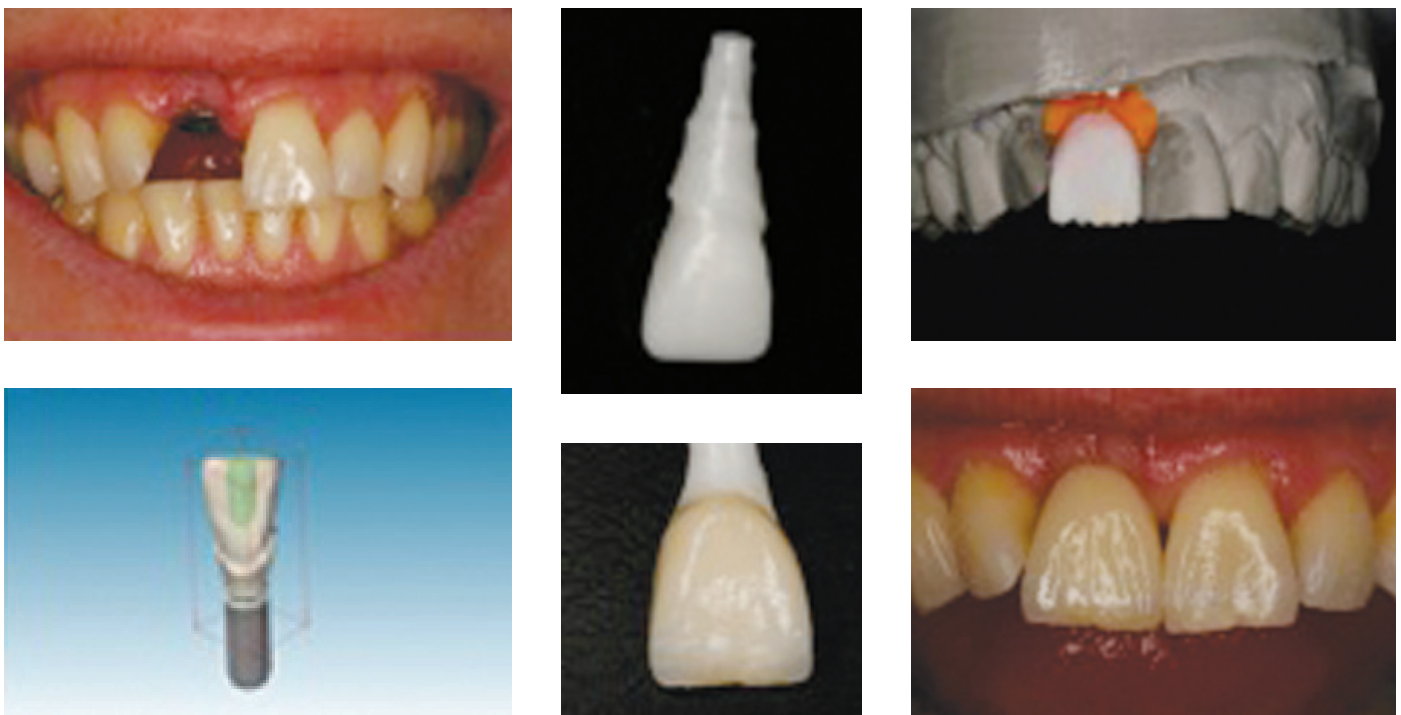
The two types of digital imaging systems currently available in the dental industry – triangulation sampling (F1 and F3) and parallel confocal (F2 and F4)

New Generation Materials

Ceramic materials have the advantage of better aesthetics and biocompatibility than metal alloys. The CAD-CAM manufacture processes and availability of zirconium dioxide as a high performance material have dramatically increased the feasibility of using ceramic for dental implant abutments, crowns and bridges.



Currently there is also active research and development into the use of ceramic dental implants. At this stage, osseointegration characteristics of the best titanium implants are far superior but this is likely to change in the future.



CAREER PATHWAYS AND IMPLANT DENTISTRY

After a couple of decades of research and development, implantology is still undergoing rapid advances and will continue to evolve with the emergence of new surgical, regenerative and restorative materials and techniques becoming available almost on a daily basis. Unfortunately, given the complex nature of the subject and the very busy curriculum, currently there is little opportunity for dentists to train in implantology during the undergraduate education. Therefore dentists who want to provide implant treatment must undertake structured postgraduate training in order to acquire the necessary clinical skills and competencies in this field of dentistry.

Thanks to the efforts of several organisations and individuals, there are numerous opportunities for structured training in the UK for today's graduates.

A dentist may wish to get involved in dental implantology at different clinical levels. The ADI, as a national charitable organisation representing UK implant dentists and their teams, provides a comprehensive portfolio of benefits to its members including support and advice, networking, education and training, mentoring, as well as CPD in this exciting field of dentistry. Anyone who is interested in getting involved with implantology or wish to improve their knowledge or skills in this field should contact the ADI for further advice.

Implant Knowledge is a Core Dental Competency

Even if your skill set does not naturally lead you towards dental implants, it is important that you know the essential principles. That way you can properly guide your patient through the consent process. It is about knowing all the options.

So What Are Your Options in Implant Dentistry?

There are three. Whole case referral, restorative practice only, referring the surgery, or you can undertake both the surgical and restorative components. But what training do you need for each? What is the legislation? What organisations can help you out?

The ADI (Association of Dental Implantology UK) can simplify the options and guide you through the postgraduate requirements that are needed for you to undertake implant work. Since its formation in 1987, the ADI has been dedicated to providing on-going postgraduate education to the dental profession in order to extend awareness of dental implant treatment as an option for improving patient oral health.

Its range of educational opportunities is varied - from specialised implant journals to Masterclasses, evening 'Study Clubs' to international Congresses. Problems can be discussed on a secure clinical forum and increasingly important implant audit facilities (Implant Logbook) can be freely accessed.

Training Opportunities for Dentists in Implant Dentistry in the UK

The current status in education of implant dentistry in the UK is based on various educational resources that provide a variety of 'implant training products' ranging from commercial/company orientated presentations/ seminars/short courses to University-led postgraduate programmes (Donos, 2009). Whilst the university based courses lead to formal qualifications (PG Diploma, MSc etc), courses organised by implant manufacturers, individual dentists or companies do not provide such qualifications. These courses can vary considerably in their content, structure, duration as well as their mode of delivery and the overall quality of training. Therefore discretion and scrutiny of the quality of a course is essential before deciding which training pathway to follow.

Clinical training in implant dentistry requires significant professional and personal commitments, which could be costly both financially and in time. Accreditation or endorsement of the quality of training, balance between academic and clinical training, availability of support from recognised mentors, impartiality, experience and the quality of the educators are some of the important factors to consider when choosing a course. Ideally implant courses should be as generic as possible to teach the principles of implant dentistry in order to address different anatomical, functional, and aesthetic requirements of patients irrespective of design features of a specific implant system.

The Association of Dental Implantology UK (ADI) is currently in the process of launching a new online resource for dentists who wish to acquire the knowledge base in implant dentistry through an online learning programme. This is a modular course made of 13 different sections written by some of the UK's most experienced implant clinicians and educators and edited by a panel of distinguished reviewers in this field. This course is intended to provide the necessary knowledge base to busy practitioners at a pace of their own choosing. Each module of the course contains interactive knowledge, application and reflection sections and is followed by quizzes to monitor progress before moving on to a different module.

Formal postgraduate qualifications are also now available in implant dentistry in the UK through universities which offer part or full time diploma/MSc programmes. As these courses require considerably more commitment they are probably more suited to clinicians who have already completed some basic training in implantology through certificate-level courses. The Diploma/MSc courses are generally spread over 2-3 years whereas, the entry level, certificate courses are delivered in a year on a part-time basis.

CAREER PATHWAYS AND IMPLANT DENTISTRY

Career pathways in implant dentistry:

TYPE OF COURSE	DURATION	QUALIFICATION
Introduction to Implantology	1-2 days	CPD course
Certificate course in Implant Dentistry	7-10 days (60 hours)	Certificate
PG Diploma	2 years part time	PG Diploma
MSc in implantology	1-2 years part time	MSc
PhD	5 years	PhD
Specialist training in oral surgery/periodontics/ prosthodontics etc	3-4 years	

In addition to those offered by UK Universities, a structured diploma course is also run by the FGDP (UK) in implant dentistry which awards “Diploma in Implant Dentistry of the FGDP(UK)” following attendance at a structured course and a strict academic and clinical assessment process based on a clinical portfolio and mentored training. This course has become highly sought after and popular in recent years given its high quality of teaching and recognition.

More recently, the RCSEd has launched a diploma by assessment. There is no requirement to attend a particular course but the candidates are encouraged to develop a broad base of knowledge relevant to implant dentistry and present a portfolio of predetermined cases. The Diploma in Implant Dentistry of the Royal College of Surgeons of Edinburgh is an examination of core knowledge and competence in the field of implant dentistry.

MEDICO-LEGAL CHALLENGES IN IMPLANT DENTISTRY

Knowing Your Patient and Knowing Your Limits

Implant dentistry is no different to all other types of treatment that involve diagnostic skills, clinical judgment, and technical expertise to execute treatment to a standard that a reasonable body of practitioners would find acceptable. There are, as in all aspects of practice areas of risk, notably at the outset of a career when learning is new and there is significant inexperience, at the end of the career when the practitioner's eyesight, motor skills and ability to operate for prolonged periods are happening, and in the mid point when confidence and competence is at a high, but financial pressures, boredom or a loss of focus occurs. The challenge for any implant dentist is to be able to demonstrate if challenged that they are suitably trained and competent to carry out the task proposed. Implant dentistry in the UK is unusual in that the GDC has issued Guidelines setting out the minimum standard of training expected by the GDC.

The common medico-legal challenges in implant dentistry can be divided into a number of categories

- Wrong diagnosis
- Right diagnosis, wrong plan
- Right diagnosis, right plan, wrong patient
- Right diagnosis, right plan, wrongly executed
- Right diagnosis, right plan, well executed, recognised complication, inadequate consent
- Any of the above with inadequate records.

The British legal system is such that ANY breach of duty that directly caused damage may well lead to a claim in negligence being successful so in preparing to practice safely from a medico-legal perspective it is imperative to look at the whole of the patient's journey and risk assess each key stage. The GDC asks a different question. Do the facts of this case amount to misconduct such that, at the time of the hearing, that the practitioner's fitness to practise is impaired. Patients can raise medico-legal challenges described above by making complaints to the practice, to the Dental Complaints Service and to the GDC. In addition patients can make claims in breach of contract and/or negligence.

Here are a few top tips to reduce your medico-legal risk.

Clinical Records

The most effective way to pre-empt a challenge is to anticipate the questions that will be raised if a patient is dissatisfied and avoidably harmed by implant treatment. The contemporaneous clinical records should show that a full history has been taken including the patient's presenting complaint and a clear indication of the patient's expectations of treatment. The challenge in any elective treatment is that the patient has been offered treatment such as an implant that they had not been aware of previously. In other words the patient has no pre-existing expectations. All of the expectations in the patient's mind result from the information and conversation with the practitioner. On occasion patient's expectations are exaggerated in an effort to persuade or encourage the patient to agree to the particular course of

treatment. In other cases, patients arrive with expectations founded on media stories and an unrealistic belief that a perfect smile can be created. Therefore from the outset of the patient's journey an assessment of the patient's expectations needs to be made and documented in the records. It follows that any unrealistic expectations must be managed and advice to the patient documented.

Marketing

There is a tension between marketing messages, designed to increase the number of patients attending a practice and taking up treatment plans and a realistic assessment of what treatment can achieve for any particular patient. The GDC's Advertising Standards Guidance sets out what the GDC expects of practice websites. These Standards apply equally to written material available to patients within practices. In addition to the GDC Guidance, any marketing material should comply with the Advertising Standards Authority Guidance which can be summed up in the following terms "legal honest decent and truthful"

Consent for Treatment

For any treatment to be legal, and to comply with GDC Guidance, a valid consent must be obtained. For consent to be valid, the competent adult patient must fully understand the nature purpose risks cost and alternatives to the treatment proposed. Where treatment is elective and expensive as implant treatment often is, the courts and the GDC would expect the patient to be fully informed about the treatment, and in reality what the patient can expect to happen. Realistic information about the chances of failure and the consequences of suboptimal outcomes need to be shared openly. This seems to run contrary to purpose of encouraging the patient to take up treatment offers and seems contrary to the business interests of the practice however GDC Standards Guidance has at the heart of it to put patients' interests above those of the practitioner and the practice. It is important that patients are given a free choice to accept or reject treatment proposals.

A practical example: Occasionally a consequence of treatment is an injury to the inferior alveolar nerve in spite of careful planning and surgical treatment. The patient may later claim that had they fully understood what a painful numbness was going to be like for them, they would not have agreed to the treatment in the first place. The challenge for the practitioner is to be able to demonstrate that they had explained the real risks and consequences of treatment, in a way that the patient fully understood. Where a serious life changing injury is possible, the chances of that happening ought to be explained, perhaps in terms of percentage chances so that a patient can do their own risk assessment. Some patients are risk averse by nature and if given any possibility of a nerve injury occurring, might look for an alternative course of treatment. This might particularly apply to patients who rely on their lip for making a living or enjoying a hobby, for example a woodwind or brass musician. Part of the assessment of the patient needs to include factors that might be relevant when considering consequences of treatment.

MEDICO-LEGAL CHALLENGES IN IMPLANT DENTISTRY

Consent forms are invaluable when linked to treatment estimates and a detailed note in the contemporaneous record showing the detail of the conversations that has taken place. The form sums up the conversation to that point. Naturally if the plan changes the records need to be able to demonstrate a variation of the consent.

Contract

An agreement to provide a service for a financial consideration is a business contract between the patient and the practitioner. If the practitioner does not deliver the treatment to the satisfaction of the patient, or changes the treatment without the agreement of the patient, the contract may be frustrated and a claim for breach of contract can follow. So for example a patient enters a contract in which it is agreed that four anterior maxillary implants will be placed to restore six missing teeth. At operation it is only possible to place three, and one of those is not in the optimal position, which results in a suboptimal appearance. The patient is disappointed and does not accept a slight midline shift. The appearance does not match the pre-op wax up and although there may have been no breach of duty of care, and the patient accepted that one fixture could not be placed during the surgery, a claim for breach of contract may succeed. The patient could achieve a full refund of fees.

What is the standard of care expected?

The courts expect that a practitioner will deliver care to a standard that is considered reasonable by a group of their peers (The Bolam Standard), so a specialist in Oral Surgery, Periodontology or Restorative Dentistry will be judged by the standard of a reasonable body of specialists. For GDP practitioners, the standard is of a reasonable body of GDP's.

The FGDP has updated the Training Standards in Implant Dentistry in 2012. This was first published in 2005, setting out what is expected of practitioners who wish to commence implant treatment in their practice. This standards guidance is normally referred to by the GDC when considering Fitness to Practise cases concerning implant dentistry. Any implant dentist needs to be able to demonstrate that their training has met (perhaps by equivalence) the standards set out by FGDP and adopted by the GDC.

Reflective practice

Individual clinical judgement is the key to successful patient care. It is crucial that practitioners know their limits and are not overambitious or optimistic when planning and delivering care. This becomes critical when unexpected or unintended consequences happen. There is no shame in seeking a second opinion from an experienced colleague, indeed patients are often pleased to be referred so that their own anxieties can be addressed. Often it is difficult for a patient and a practitioner to discuss complications openly and frankly without the intervention of a third party. In terms of managing patient expectation it is much better to remain in control of the situation by agreeing a suitable second opinion practitioner with the patient, rather than letting the patient

seek their own, perhaps less sympathetic second opinion. When an unexpected or adverse incident happens, the future is often determined by the candour and openness of the practitioner in explaining the events to the patient. Patients are troubled by inconsistent explanations and apparently misleading remarks. This means that patients are much less likely to complain or sue if the practitioner maintains open honest lines of communication and clearly cares about and for the patient in good times and bad. Knowing your patient well makes these conversations more effective. Sensible resolutions to problems can frequently be found by working constructively with the patient, rather than by working against each other with increasing mutual mistrust.

Dr Stephen Henderson

Senior Dento-legal advisor for Dental Protection Ltd



Association of Dental Implantology

EDITOR IN CHIEF:	EDITORS:	AUTHORS:
Cemal Ucer	Simon Wright Kelly Slade	Catherine Drysdale Koray Feran Philip Friel Stephen Henderson Craig Parker David Speechley Cemal Ucer Simon Wright

THE ASSOCIATION OF DENTAL IMPLANTOLOGY UK

The ADI is a non-profit making registered Charity dedicated to the provision of on-going education to the profession and to raising the awareness of good standards of practice for the benefit of the public. Membership is open to all who have an active interest in dental implants. Established over 20 years ago to meet the needs of the GDP eager to learn about osseointegration techniques, current membership stands in excess of 1,900. The ADI extends its membership services to encompass the entire dental implant team and offers tangible benefits to dental implant professionals at all levels of ability. Full details are available at www.adi.org.uk, or please call 020 8487 5555.

The Association of Dental Implantology,
98 South Worple Way, London, SW14 8ND
Tel: 020 8487 5555 Web: www.adi.org.uk



For further information on becoming a member of the ADI please contact us:

ONLINE: www.adi.org.uk

EMAIL: info@adi.org.uk

TELEPHONE: +44 (0)20 8487 5555



@ADI_dental



ADIdentaluk